

Conditioned medium derived from mesenchymal Stem cells regenerates¹ defected articular cartilage

Masumeh Zirak Javanmard¹, Mojtaba Karimipour^{2*}, Fatemeh Atabaki Pasdar³

Received: 18 May, 2018; Accepted: 12 Aug, 2018

Abstract

Background & Aims: One of cell-based technical issues associated with cartilage repair assay is delivering cells to the site of the parts where damage is created. Mesenchymal stem cells (MSCs) with their chondrogenic potential are ideal candidates for cartilage regeneration. High expression of cartilage hypertrophy markers by MSCs would result in apoptosis and ossification. This investigation is attempted to find out if paracrine factors secreted from MSCs can regenerate damaged articular in a rat model.

Materials & Methods: Osteoarthritis (OA) was induced in eighteen adult rats by intra-articular (IA) injection of monosodium iodoacetate (MIA) into right knee. Then the animals were randomly divided into three groups (n=6). Control group received IA injection of vehicle; MSCs group received a single IA injection of MSCs (2.5×10⁵/50μL DMEM) and conditioned medium (CM) group received a single IA injection of CM, meanwhile six left intact knee joints were taken as the normal group. After four weeks, the animals were sacrificed by overdose injection of ketamine and then, the distal end of femur removed and fixed in formalin. After decalcification using formic acid, histological slides obtained. In this study number of chondrocytes and morphology of articular surface were evaluated.

Results: Four weeks after treatment, gross and microscopic evidence of articular cartilage of distal end of femur cartilage demonstrated the significant (p<0.05) healing of OA joints in group treated with MSCs. Also, in CM group significant increase in number of chondrocyte (p<0.05) and decrease of degenerated holes width was observed compared to the control group.

Conclusion: Given the deficiencies of cell-therapy in OA, a potential for repair of degenerated articular cartilage is thought possible to be represented by cell free CM.

Key words: Conditioned medium, Osteoarthritis, Mesenchymal stem cells, Mono-iodoacetate

Address: Department of Anatomy, Urmia University of Medical Sciences, Urmia, Iran

Tel: +98 44 3327698

Email: Mojtaba_karimipour@yahoo.com

Introduction

Osteoarthritis (OA) is a common painful disease, which disables a large number of individuals. It typically affects the function of several joints, among which knee

is the most frequent one and is considered the most important clinically. This disease basically forms a major cause of pain and disability among most individuals of both sexes (1). The knee joint acts as a

¹ Urmia University of medical sciences, Department of Anatomy, assistant professor, Urmia, Iran

² Urmia University of medical sciences, Department of Anatomy, associate professor, Urmia, Iran (Corresponding Author)

³ Urmia University of medical sciences, Department of Anatomy, assistant professor, Urmia, Iran

channel for transferring the weight of the body and also has complicated movements, articular cartilage and synovial membrane(2).The articular cartilage tissue consists of specialized cells called chondrocytes and extracellular matrix (ECM) including collagen type II, aggrecans and proteoglycan. This unique composition of cartilage enables the tissue to keep a balance in mechanical structure and flexibility (3).

In mild cases of OA, treatment methods may include pharmacologic and non-pharmacologic agents for temporary relief. However, with progress of diseases, several therapies like hyaluronic acid, steroids intra-articular injection and arthroplasty have been used for OA(4).Cell therapy is a biological therapy and form of regenerative medicine used as modern research system. It is known that there is no effective pharmacological agents for OA, and it is needed to develop biological therapy in basic science viewpoint (5).

The inherent capability of Bone Marrow derived stem cells (BMSCs) help them to easily isolate and massively expand in culture. They migrate to injury sites and by inherent capacity differentiate to chondrocytes (3). They possess the capacity to therapeutic elements such as anti-inflammatory and immunosuppressive factors. Direct injection of MSCs into OA model significantly promoted the cartilage regeneration improved function and pain (6).

BMSCs have an inherent potentiality to undergo hypertrophy and this tendency can be considered as a risk factor in articular cartilage repair (7). Pro-angiogenic factors, like vascular endothelial growth factors are released by hypertrophic chondrocytes, and these factors are responsible for vascularisation of tissue (3). Hypertrophic cartilages have been recognized be significant suppliers of nutrients to the developing cartilage (8).

According to researches, regenerative potential of MSCs mainly is related to secreted large quantities of bioactive factors that are trophic and exhibiting anti-

inflammatory and anti-apoptotic activities(9). MSCs generated conditioned medium contain a variety of growth factors which support the repair of injured tissues. The MSCs participate in reduction myocardial infarct size through its secretions (10) and paracrine factors like endothelial progenitor cell (11). Reportedly, CM from MSCs pre –treated with cytokines, promote osteoblast proliferation and differentiation (12).

The aim of present study was to evaluate the effects of cell-free administration of paracrine factors which are released by cultured BMSCs in regeneration of articular cartilage in OA knee of rats.

Materials and Methods

Induce articular cartilage defect:

Having obtained approval from University of Medical Sciences of Urmia (UMSU) Animal Ethical Committee, we initiated the study. Induction of OA was performed in right knee of eighteen male Sprague-Dawley rats, with average of 250 - 300 gr. A single intra-articular injection of Mono-iodoacetate (sigma) 20 μ l, was done through the patellar ligament into the right knee joint cavity of rats anesthetized with isoflurane 2% in co2 (13). Then experimental animals were assigned to three group equal (6 each) treatment groups. Rats in the MSCs treatment group received single injection of 2.5×10^5 cells in 50 μ l DMEM. The CM Group was treated with the same volume of conditioned medium. The control group was treated with the same volume of DMEM medium. The six intact left knees served as a normal.

Preparation of MSCs and CM:

Bone marrow samples were pushed out from bone marrow cavity of tibia through syringing and was diluted (1:3) with Dulbecco's Modified Eagle's Medium (DMEM) and centrifuged at 1200 g for 5 minutes.The supernatant was abandoned and the cells pellet was washed with PBS, then was re-suspended in DMEM

(sigma) with 10% fetal bovin serum and pen strep 1% (gibco), next incubated at 37°C and 5% CO₂ in plastic culture flask. In the third day of culture, the nonadherent cells were washed and the medium was changed every 3 days. After 3 passages the cells were detached with 0.25% trypsin/0.1% EDTA and recultured until reaching 80% confluence. (14). Each animal in MSCs group received a single IA injection of 2.5×10^5 cells on its right knee. Culture medium was harvested from the cells 48h later, then the collected medium was centrifuged at 1500 rpm for 5 min. The supernatants were used as conditioned medium (CM).

Gross study:

Overdose anesthesia was used to sacrifice the animals after four weeks. Two blinded examiners examined the dissected right and left knee of the rats under stereomicroscope (Motic). International Cartilage Repair Society (ICRS) scoring system was used to score macroscopic evaluations. Scores ranging from point 0 (0% repair of defect depth) to 4 point (more than 75% repair) were appointed for overall healing (15).

Histological staining:

The distal femurs were removed and fixed in 10% formalin at 4°C and decalcification was done in formic acid (5%) for three days. Automated tissue processor was run on the specimen for 24 hours and were embedded in paraffin. Serial sections of 5 µm were cut horizontally along the condyles. Histological staining was performed with hematoxylin-eosin and bone was distinguished from cartilage by toluidine-blue. Mallory's trichrome was carried out in order to count of chondrocytes based on the guidelines provided by the manufacturer (Bio-Optica, Milano, Italy).

Morphometric assessment:

The samples are serially sectioned at 5 µm, and then stained with Mallory's trichrome. Quantification of the intermediate and deep zones that contained the chondrocytes was performed by using a 10 × objective lens with a 100 squares grid. The average of the number of chondrocytes per case was obtained in 4 squares in each slide and results were presented as five slides in each group. Dark nucleus and eosinophilic cytoplasm color of the cells were easily distinguished from the blue-stained matrix surrounding the cells. Furthermore, in cavities created in articular cartilage after induction of OA, the depth and width of the biggest cavity were measured with a digital microscope camera (Moticam 2000, 5.0 megapixels).

Statistical analysis:

The data were examined by One – Way ANOVA using SPSS 16 software (USA). All results were shown as means ± standard deviation (SD) and a p value <0.05 was determined as statistically significant.

Results

Macroscopic results:

The surface of articular cartilage (AC) in all groups was evaluated by visual cartilage regeneration under stereomicroscope (Fig.1) and the ICRS was used to score the outcomes. All femoral distal ends of the normal group were quantified to be intact. The control OA group turned out to have the highest lesion score (3.16 ± 0.16 points). The less cartilage lesion score of 1.16 ± 0.24 points was observed in MSCs group. The Difference between MSCs and control OA was statistically significant ($P < 0.05$). The knee joints of the CM group compared to that of OA group showed a little, but not significant, more improvement (2.18 ± 0.15 points). This score in MSCs group was significantly higher than CM group ($p < 0.05$). All femoral articular cartilages of normal group were intact.

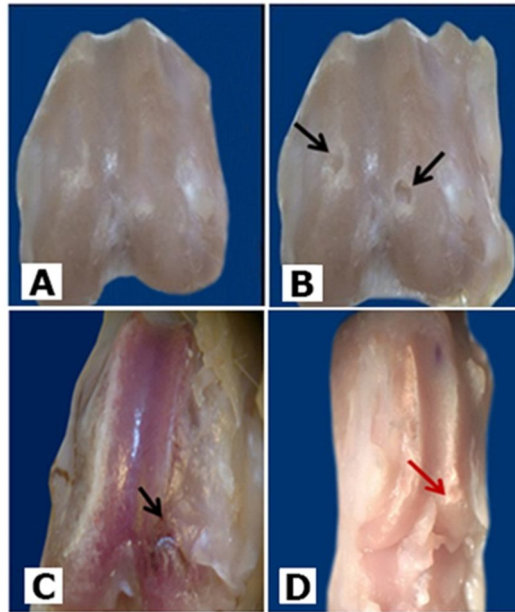


Figure 1. Macroscopic images of femoral articular surface. A; normal, B; OA control, C; MSCs and D; CM group

Microscopic and morphometric results:

H& E and Mallory trichrome stained sections revealed that microscopic structure of the articular cartilage of the normal rats was completely normal. In

addition, sections of osteoarthritic (OA) group showed disorientation, clustering and decrease in the mean chondrocytes (Fig.2).

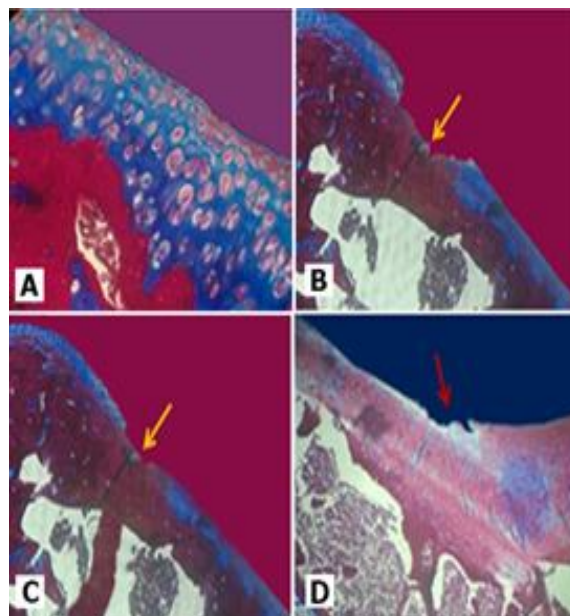


Fig. (2): Histological analysis by Mallory trichrom of the rat femoral condyle. Photomicrograph of the normal group showed that the chondrocytes were intact in all zones 100x (A). The osteoarthritis group demonstrated degeneration of superficial, transitional and briefly deep zones (B). Data obtained from the MSCs group demonstrated degeneration of superficial zone of articular cartilage, 40x (C) and moderate regeneration was observed in CM group (D).

Four weeks after induction of OA, the MSCs group significantly ($p < 0.05$) showed a regeneration in the form of proliferating cells and increase in the mean number of chondrocytes compared to OA control group. There was also a significant decrease in depth and width of the articular cartilage holes ($p < 0.05$) compared to OA control group.

Sections of the CM group (treated by conditioned medium) 4 weeks after MIA injection showed the significant ($p < 0.05$) increase in the mean number of chondrocytes and reduction in the lesion depth compared to the OA group. Meanwhile, the number of chondrocytes in MSCs group was significantly higher than CM ($p < 0.05$) (Fig.3. Table1).

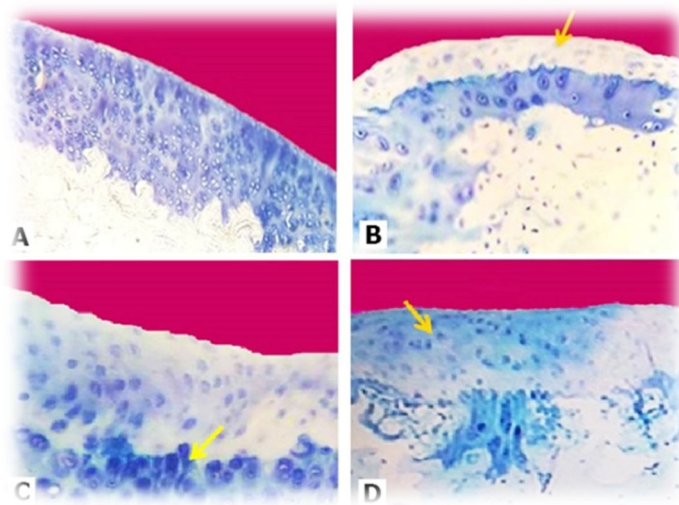


Fig.3: Histological analysis by toluidin blue staining of the rat femoral condyle. The cartilage thickness of the knee joint was normal in normal group (A), in the OA group was lesser than normal. The number of chondrocytes and the intensity of the staining of extracellular matrix decreased (B). The MSCs group exhibited good cartilage thickness, increased chondrocytes number and the intensity of the matrix (c). A slight, change was observed in the CM group but cartilage thickness and the intensity of the staining of matrix turned out to be less than MSCs group (D). Original magnification 40 x.

Table 1. The number of chondrocytes, width and depth of cartilage holes in all groups.

Data are presented as mean ± SD

Groups	Chondrocytes number	Width (µm)	Depth (µm)
Normal	115.33± 2.186	.000±.00000	.0000±.00000
OA	18.83± 2.587	.5000±.07298	.5630±.13103
OA + MSCs	75.00± 5.780**	.3416±.04036**	.2166±.03747**
OA + CM	62.24± 4.604**	.4533±.04730	.4166±.09898

$P < 0.05$ vs OA group**

OA: Osteoarthritis MSCs: Mesenchymal stem cells CM: Conditioned medium

Discussion

Several clinical and laboratory studies from different parts of the world are reported on the therapeutic effect of BMSCs administration on patient or laboratory animals with OA. For more than a decade, treating OA through cell-therapy has been the center of attention in many clinical trials. The current investigation examined the use of MSCs in healing the occurrence of osteoarthritis lesions after injection of MIA, but the most important principle in this study was whether the factors secreted by the MSCs, with no physical presence of cells could have a role in OA healing.

For this purpose, IA injection of MSCs and CM were used and lesions healing were evaluated by ICRS grading and morphometric analysis. In the MSCs group, a tissue similar to cartilage was formed. The histological study showed regeneration of lesions in the form of filling the holes, decrease in the depth of degenerated areas and increased chondrocytes after cell therapy. These apparently immature big-nucleus-chondrocytes may change into a mature ones after a long time. The MSCs generated ECM repairs the injured cartilage (7). Studies have shown that BMSCs can produce matrix and express the collagen type II markers by releasing some soluble growth factors (16).

Several studies have used BMSCs to treat OA but unfortunately one of the problems of cell therapy is the potential chondrogenic hypertrophy of differentiated cells. Collagen (COLX) and matrix metalloproteinases (MMP13) and phosphorylated alkaline phosphatase are the hypertrophic markers expressed highly by BMSCs (17, 18). Increase in cell volume causes changes in intracellular and extracellular osmolality, ECM degeneration and increase in the amount of intracellular organelles (19). For inhibition of chondrogenic hypertrophy blocking of vascular endothelial growth factor (VEGF) with soluble Fit-1, was investigated to

the control of angiogenesis during chondrogenic differentiation in stem cells derived from skeletal muscles in a rat model of OA. This cell therapy prevents angiogenesis, which in turn, postpones cartilage healing process (20).

In present experiment, conditioned medium or secretions of the BMSC could macroscopically and histologically repaired the OA cartilage and increased significantly chondrocytes number. Previous in vitro relevant researches have indicated that the conditioned medium reduced myocardial infarct size (10). MSCs may contribute to regeneration not only by direct differentiation but also by the release of growth factors such as IGF- β , VEGF, PDGF and b FGF (21) and antiapoptotic (22) and antioxidative factors (23). In this study, growth factors which secreted from MSCs could have regenerative effect on AC without the presence of Cell. The relative increase of chondrocytes and ECM, mild regeneration of depth and width of osteoarthritic holes in AC are reparative evidences, probably due to the presence of growth factors secreted by MSCs inside the medium. It seems that results of healing effects of MSCs secretions should be used in OA cases.

Conflict of interest

The authors declare that there is no conflict of interest.

Acknowledgments

This study was supported financially by Deputy of Research, Urmia University of Medical Sciences. We wish to extend our appreciation to Urmia University of Medical sciences (No; 1523) and Dawood Asgari (MS student of anatomy).

References

1. Mobasheri A, Kalamegam G, Musumeci G, Batt ME. Chondrocyte and mesenchymal stem cell-based therapies

- for cartilage repair in osteoarthritis and related orthopaedic conditions. *Maturitas* 2014; 78(3): 188-98.
2. Johnstone B, Alini M, Cucchiari M, Dodge GR, Eglin D, Guilak F, et al. Tissue engineering for articular cartilage repair—the state of the art. *Eur Cell Mater* 2013; 25: 248-267.
 3. Chen S, Fu P, Cong R, Wu H, Pei M. Strategies to minimize hypertrophy in cartilage engineering and regeneration. *Genes Dis* 2015; 2(1): 76-95.
 4. Buckwalter JA, Saltzman C, Brown T. The impact of osteoarthritis: implications for research. *Clin Orthop Relat Res* 2004; 427: 6-15.
 5. Sheehy EJ, Vinardell T, Toner ME, Buckley CT, Kelly DJ. Altering the architecture of tissue engineered hypertrophic cartilaginous grafts facilitates vascularisation and accelerates mineralisation. *PloS one* 2014; 9(3): e90716.
 6. Jo CH, Lee YG, Shin WH, Kim H, Chai JW, Jeong EC, et al. Intra-articular injection of mesenchymal stem cells for the treatment of osteoarthritis of the knee: a proof-of-concept clinical trial. *Stem Cells* 2014; 32(5): 1254-66.
 7. Pelttari K, Winter A, Steck E, Goetzke K, Hennig T, Ochs BG, et al. Premature induction of hypertrophy during in vitro chondrogenesis of human mesenchymal stem cells correlates with calcification and vascular invasion after ectopic transplantation in SCID mice. *Arthritis Rheum* 2006; 54 (10): 3254-66.
 8. Blumer, MJ, Longato S, Fritsch H. Structure, formation and role of cartilage canals in the developing bone. *Ann Anat* 2008; 190 (4): 305-15.
 9. Shrestha C, Zhao L, Chen K, He H, Mo Z. Enhanced healing of diabetic wounds by subcutaneous administration of human umbilical cord derived stem cells and their conditioned media. *Int J Endocrinol* 2013; 2013: 592454.
 10. Leo T, Sai K, Fatih A, Jeffrey SA, Imo EH, Pieter A, et al. Reduction of myocardial infarct size by human mesenchymal stem cell conditioned medium. *Stem cell Res* 2008; 1(2): 129-37.
 11. Di Santo S, Yang Z, Wyler von Ballmoos M, Voelzmann J, Diehm N, Baumgartner I, et al. Novel cell-free strategy for therapeutic angiogenesis: in vitro generated conditioned medium can replace progenitor cell transplantation. *PLoS One* 2009; 4(5): e5643.
 12. Konala VB, Mamidi MK, Bhonde R, Das AK, Pochampally R, Pal R.. The current landscape of the mesenchymal stromal cell secretome: a new paradigm for cell-free regeneration. *Cytotherapy* 2016; 18(1): 13-24.
 13. Horváth Á, Tékus V, Boros M, Pozsgai G, Botz B, Borbély É, et al., Transient receptor potential ankyrin 1 (TRPA1) receptor is involved in chronic arthritis: in vivo study using TRPA1-deficient mice. *Arthritis Res Ther* 2016; 18: 6.
 14. Zirak Javanmard M, Asgari D, Karimipour M, Atabaki F, Farjah G. Stem Cells Inhibit Proteoglycan Degeneration in a Rat Model of Osteoarthritis. *Gene Cell Tissue* 2015; 2(4): e31011.
 15. van den Borne MP, Rajmakers NJ, Vanlauwe J, Victor J, de Jong SN, Bellemans J, et al. International Cartilage Repair Society (ICRS) and Oswestry macroscopic cartilage evaluation scores validated for use in Autologous Chondrocyte Implantation (ACI) and microfracture. *Osteoarthritis Cartilage* 2007; 15(12): 1397-402.
 - 16., Hennig T, Lorenz H, Thiel A, Goetzke K, Dickhut A, Geiger Fand Richter W. Reduced chondrogenic potential of adipose tissue derived stromal cells correlates with an altered TGFβ receptor and BMP profile and is overcome by BMP-6. *J Cell Physiol* 2007; 211(3): 682-91.
 17. Mackie EJ, Tatarczuch L, Mirams M. The skeleton: a multi-functional complex organ. The growth plate chondrocyte and endochondral ossification. *J Endocrinol* 2011; 211 (2): 109-21.
 18. Hellingman CA, Koevoet W, van Osch GJ., Can one generate stable hyaline cartilage from adult mesenchymal stem cells? A developmental approach. *J Tissue Eng Regen Med* 2012; 6(10):e1-e11.

19. Jones BA, Pei M. Synovium-derived stem cells: a tissue-specific stem cell for cartilage engineering and regeneration. *Tissue Eng Part B Rev* 2012; 18(4): 301-11.
20. Matsumoto T, Cooper GM, Gharaibeh B, Meszaros LB, Li G, Usas A, Fu FH, et al. Cartilage repair in a rat model of osteoarthritis through intraarticular transplantation of muscle-derived stem cells expressing bone morphogenetic protein 4 and soluble flt-1 *Arthritis Rheum* 2009;60(5): 1390-405.
21. Schmitt A, van Griensven M, Imhoff AB, Buchmann S. Application of stem cells in orthopedics. *Stem cells int* 2012; 2012: 394962.
22. Wang SP, Wang ZH, Peng DY, Li SM, Wang H, Wang XH. Therapeutic effect of mesenchymal stem cells in rats with intracerebral hemorrhage: reduced apoptosis and enhanced neuroprotection. *Mol Med Rep* 2012; 6(4): 848-54.
23. Okazaki T, Magaki T, Takeda M, Kajiwara Y, Hanaya R, Sugiyama K, et al. Intravenous administration of bone marrow stromal cells increases survivin and Bcl-2 protein expression and improves sensorimotor function following ischemia in rats. *Neurosci Lett* 2008; 430(2): 109-14.