

## Pneumoperitoneum as a Rare Clinical Manifestation in two Patients with COVID-19: A Case Series Study

Morteza Amestejani<sup>1</sup>, Mahbubeh Moradi<sup>2</sup>, Kazhal Mobaraki<sup>3</sup>, Jamal Ahmadzadeh<sup>4</sup>,  
Mohammad Payandeh<sup>5</sup>, Arash Aliasghari<sup>6</sup>, Maryam Salamatbakhsh<sup>7</sup>, Awat Yousefiazar<sup>8\*</sup>

Received 10 April 2022, Accepted for publication 23 Nov 2022

### Abstract

**Background & Aims:** Pneumoperitoneum is characterized by the presence of air inside the peritoneal cavity, which may be the result of a perforated hollow organ in GI (Gastrointestinal) tract, requiring emergency surgical intervention. However, pneumoperitoneum is known to be spontaneous, nonsurgical, or unexplained in some cases without perforation. The present study is a case series study, introducing two cases of pneumoperitoneum in the patients with COVID-19.

**Case presentation:** The first case was a 70-year-old woman with COVID-19 who underwent laparotomy, and no perforation was detected in her as the source of pneumoperitoneum under direct observation. The second case was a four-year-old girl who was referred to hospital after a car accident as pedestrian. After taking a CT scan, COVID-19 was diagnosed accidentally without any previous sign. After diagnosing pneumoperitoneum, since there was no symptom of perforation or peritonitis, the patient was actively monitored during the hospitalization period and discharged on day 8 of hospitalization in a general good condition.

**Discussion & Conclusion:** Evidence from a previous study suggests that coronavirus has a high propensity to gastrointestinal tract. Enteropathic viruses can directly damage the intestinal mucosa and cause gastrointestinal complaints in the patients. Invasion of the virus into the intestinal wall can increase the permeability of the intestinal wall, leading to easier invasion of pathogens over the large intestine tract and intestinal complaints (including pneumatosis) by reducing the function of intestinal barrier. Increasing permeability of the intestinal wall may be a factor of pneumoperitoneum.

**Keywords:** Coronavirus, COVID-19, Pneumoperitoneum, Spontaneous

**Address:** Department of Surgical technology, School of Allied Medical Sciences, Urmia University of Medical Sciences, Urmia, Iran

**Tel:** +989141672768

**Email:** Yousefiazar.a@umsu.ac.ir

### Introduction

Pneumoperitoneum is recognized by the presence of air within the peritoneal cavity, which may be the result

of a perforated hollow organ and requires emergency surgical intervention (1). The most common cause of pneumoperitoneum is perforation of GI (90% of cases).

<sup>1</sup> MD, Department of General Surgery, School of Medicine, Imam Khomeini Hospital, Urmia University of Medical Sciences, Urmia, Iran

<sup>2</sup> Instructor of Critical Care Nursing, School of Nursing, Gerash University of Medical Sciences, Gerash, Iran

<sup>3</sup> MSc in Epidemiology, Social Determinants of Health Research Center, Urmia University of Medical Sciences, Urmia, Iran

<sup>4</sup> MSc in Epidemiology, Social Determinants of Health Research Center, Urmia University of Medical Sciences, Urmia, Iran

<sup>5</sup> MSc of Critical Care Nursing, Urmia University of Medical Sciences, Urmia, Iran

<sup>6</sup> MSc. Student, Operating Room Technology, Operating Room Department, School of Paramedical Sciences, Iran University of Medical Sciences, Tehran, Iran

<sup>7</sup> MSc in Critical Care Nursing, Urmia University of Medical Sciences, Urmia, Iran

<sup>8</sup> Ph.D candidate in Nursing, Department of Surgical technology, School of Allied Medical Sciences, Urmia University of Medical Sciences, Urmia, Iran (Corresponding Author)

Nevertheless, 5-15% of cases of pneumoperitoneum can be without perforation and be spontaneous, nonsurgical, or unexplained (1, 2). Spontaneous pneumoperitoneum (PP) can be due to intra-thecal, intra-abdominal, gynecological, iatrogenic, or other miscellaneous factors (2, 3). Among the thoracic factors, mechanical ventilation, pneumothorax, CPR, tracheal rupture, sternotomy, and blast injuries are the most common causes (3). Ventilator-induced barotrauma is one of the most frequent intra-thoracic factors that can cause spontaneous pneumoperitoneum (4).

Idiopathic conditions of PP are much rarer, because there is no clear etiology and there is neither intra-abdominal perforations nor other known factors for free intra-abdominal gas presence (2). Peritonitis is the most common complaint of pneumoperitoneum. In addition, the presence of sub-phrenic air inside the peritoneum on radiography and CT scan of the chest and abdomen is a pathological finding related with pneumoperitoneum (2, 3). In most cases, pneumoperitoneum requires immediate exploratory surgery and intervention. Idiopathic pneumoperitoneum is usually reported after negative laparotomy results. Spontaneous pneumoperitoneum creates a significant dilemma for management, especially in cases where the symptoms of peritonitis are not observed or when the cause is not known before laparotomy (2, 5).

SARS-COV-2 (Severe Acute Respiratory Syndrome Coronavirus 2) is a positively charged single-stranded virus which belongs to the beta coronavirus family. SARS-COV-2 enters the cells via ACE2 (angiotensin-converting enzyme 2) receptors (6, 7). ACE2 as the target enzyme of SARS-COV-2 had its highest levels in the lungs, small intestine and vascular system, and due to the high expression of ACE2 in small intestine absorptive enterocytes, the gastrointestinal tract can be highly susceptible to damage by the virus (8). The most commonly reported findings from various studies related to gastrointestinal complaints include nausea,

vomiting, and abdominal pain (8, 9). Some studies have also reported degeneration, necrosis, shedding of gastrointestinal mucosa, and intestinal bleeding during hospitalization. Moreover, increasing intestinal wall thickness, pneumatosis and the presence of gas in portal vein present a wide range of symptoms indicating involvement and serious damage to the gastrointestinal tract due to coronavirus infection (6, 8). Despite numerous findings and reports of gastrointestinal involvement, little information is available on how the virus works and the mechanism of intestinal damage; for which further studies are needed. The present study is a case series introducing two cases of pneumoperitoneum in the patients with coronavirus. To the best of our knowledge, there was no other reports of pneumoperitoneum following COVID-19 worldwide.

## Case Presentation

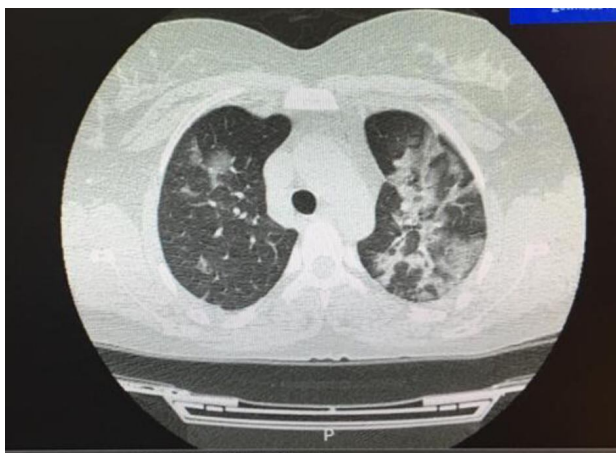
### First Case:

The patient was a COVID-19 positive 70-year-old woman with no history of previous disease other than COVID-19 (Figure 1). She was presented with abdominal pain diffusing into the epigastrium and right upper quadrant (RUQ). The patient's pain had started two days ago with an upward trend. The pain was not positional, did not spread anywhere, and had no relationship with eating. The patient had nausea and anorexia, but did not vomit and reported normal bowel function.

Vital signs on arrival were as follows: PR: 85, RR: 19, BP: 105/75, T: 36.8, SaO<sub>2</sub>: 90%. In the clinical history of the last 3-4 days, mild shortness of breath and occasional dry cough were mentioned. No fever was detected on examination, and the patient had no underlying disease nor a previous history of surgery. On pulmonary examination, both hemithoraces were symmetrical. There was no wheezing and no accessory muscles breathing. However, crackles were heard at the base of both lungs. In abdominal palpation, there was

tenderness in RUQ, but there was no guarding or rebound tenderness. No organomegaly and mass were touched. On cardiac examination, the heart sounds were normal, and there were no extra sounds. Results of initial

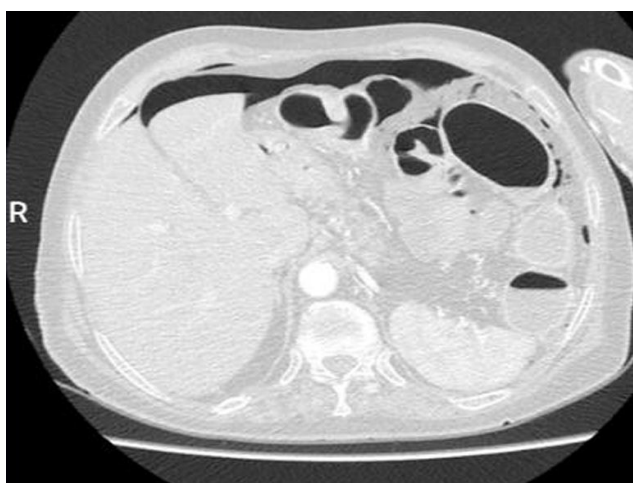laboratory tests were as follows: WBC: 3800 (Neut: 57%, Lymph: 31%), Hb: 11.2, Plt: 485000, BUN: 42, Cr: 1.2, Na: 141, K: 4.8 3- CRP: 2+, and ESR: 38.



**Fig. 1.** thoracic CT scan in the axial plane, showing ground glass appearance in the base of both lungs

After requesting a chest radiograph for the patient, pneumoperitoneum was detected (Figure 2), and so, she was transferred to the general surgery ward. After six hours of hydration, vital signs were as follows: PR: 71, RR: 16, BP: 115/80, T: 36.8, and SaO<sub>2</sub>: 92%. Urinary output was 550cc/6h, and CVP was 9 cmH<sub>2</sub>O. After

taking ECG and visit by an internal medicine physician, we decided to perform exploratory laparotomy to find the source of pneumoperitoneum. In this way, after pre-operative preparations, the patient was transferred to the operating room.



**Fig. 2.** Thoracic CT scan in the axial plane, showing sub-phrenic free air

**Surgical Procedure:**

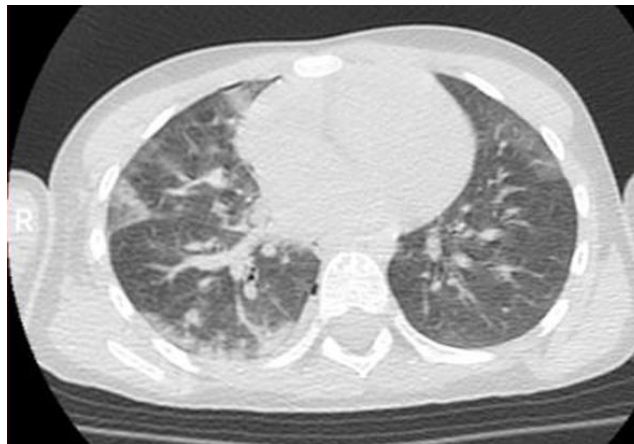
Under general anesthesia, surgery was performed in supine position on the operating table. After prep and drape, midline incision was made. After entering the abdomen, no gas or discharge was observed. The abdomen lacked any pathologic findings. After entering the lesser sac, the posterior region of stomach was evaluated, and no pathological signs were observed. The small intestine was evaluated from the ligament of Treitz, and no restrictions were detected. Upon further evaluation, the omentum had adhered to Left Upper Quadrant (LUQ), which was released. The colon was examined from the ileocecal valve. The hepatic flexure had adhesions to the liver that were released. No other pathological findings were seen in that area. Dilatation of the loops was evident from the descending colon to the sigmoid, but there was no stenosis or tumor in favor of obstruction on inspection. Finally, the abdomen was closed after implanting a corrugated drain in RUQ.

**Second Case:**

The patient was a 4-year-old girl who suffered from multiple trauma due to a car accident as pedestrian, and

was brought to the emergency room about 30 minutes after the accident. Vital signs of the patient upon arrival were as follows: PR: 118, RR: 20, BP: 100/65, T: 37.2, and SaO<sub>2</sub>: 92%. Upon admission, the patient had spontaneous breathing, was alert, and had a fixed cervical collar. On chest observation, movement on both sides of the chest was normal, and there was no dilation in the jugular arteries. Pulmonary sounds were not decreased but there were brief pulmonary rales on both sides. On chest palpation, no sign of tenderness was detected, and the lungs were normal on chest percussion. At first, the patient complained of slight pain in the neck. There was no pathological finding in e-FAST evaluation, and further examination of the chest did not reveal any sores or scratches, paradoxical movements, or subcutaneous emphysema.

On abdominal examination, no distension was observed, and intestinal sounds were normal. No tenderness, guarding or organomegaly were observed. The pelvis was stable and did not show any tenderness on examination. The perineal area was also normal. On evaluation, the limbs were normal and had not any sign of swelling, sores, or bleeding.

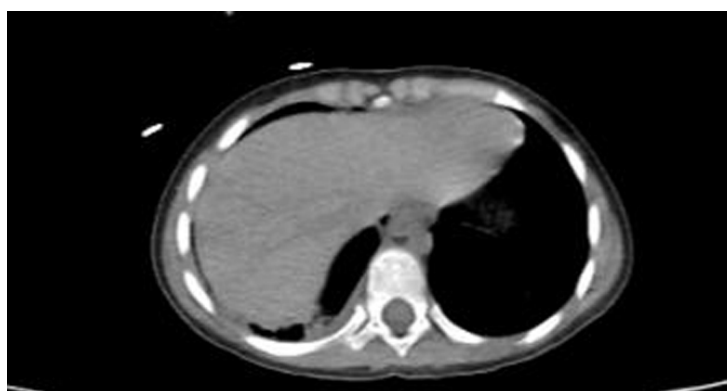

**Fig. 3.** thoracic CT scan in the axial plane showing ground glass appearance in the base of both lungs

Chest, pelvic and lateral cervical X-rays were performed. In chest X-ray evaluation, following suspicion of narrow air rim in the chest wall and uncertainty of pneumothorax, chest CT was performed, which accidentally noticed the ground glass opacity similar to typical COVID-19 view. Further examination by a radiologist confirmed the presence of white spots in various parts of the lung in favor of COVID-19 (Figure 3). Nasal soap RT-PCR test was performed

immediately for the patient, which confirmed the observations on CT scan.

The patient was visited by a pediatric infectious disease specialist, and the COVID-19 treatment protocol started under the supervision of a pediatrician. During inspection of Chest CT scan and in the lower sections of the lung CT scan, we noticed free air in the abdomen and below the diaphragm in favor of pneumoperitoneum (Figure 4).



**Fig. 4.** Thoracic CT scan in the axial plane showing sub-phrenic free air

Due to the lack of symptoms in favor of peritonitis, the patient was admitted to an isolated ICU. At the time of admission to ICU, the patient underwent abdominal CT scan with contrast IV and with oral gastrographin, which did not have an intraperitoneal or retroperitoneal contrast agent leak, while the contrast agent slowly progressed toward the anus.

Due to the absence of peritonitis symptoms, surgical intervention was not on the agenda. Thus, the patient was actively monitored in the form of serial abdominal examinations and continuous evaluation of vital signs by the surgical team as well as daily examinations of pediatric infectious disease specialists by COVID-19 treatment team in the intensive care unit. CBC tests were performed serially. The results of examinations and laboratory tests over five days did not show any findings

in favor of intra-abdominal rupture. On the fifth day, the patient became PO and appropriate tolerance of PO was observed.

According to the examinations and normal results of laboratory tests and by observing the order of the surgeon and approval of the pediatric infectious disease specialist to continue care at home, the patient was discharged on the eighth day of hospitalization in good overall condition. At the time of discharge, the test results indicated lack of evidence of leukocytosis, leukopenia, anemia, or thrombocytosis, and biochemical tests were also normal. She had good oral feeding and gas and defecated normally. The patient was revisited on the second, seventh, and fourteenth days after discharge, which showed no pathological lesion in favor of pneumoperitoneum in the abdominal viscera.

## Discussion

The most common cause of pneumoperitoneum is the rupture of abdominal viscera, known as acute peritonitis, which is a surgical emergency requiring emergency surgical intervention (10). Spontaneous pneumoperitoneum is an uncommon condition that can occur due to a variety of reasons, including intra-abdominal, intra-thoracic, gynecological, iatrogenic, or other factors (2, 3). Idiopathic pneumoperitoneum is a much rarer condition in which, none of the perforation and spontaneous factors are the cause of pneumoperitoneum (2, 10).

In the present study, the possibility of visceral perforation was raised in the first case, and in her order to exclude this diagnosis, direct observation of abdominal viscera through laparotomy was performed. However, after laparotomy, no signs of perforation were observed. In the second case, although the patient was referred to the emergency room following an accident, since no trauma and injury were observed in the thoracic and abdominal organs and also because of lack of any complaints or symptoms in the patient, it was decided to monitor the patient actively. Patient follow-up revealed that active monitoring was the best medical decision that could be made for the patient. In fact, the second case was a patient with no signs of COVID-19, and the disease was diagnosed accidentally by the chest CT scan taken with the aim of initial post-accident assessments to exclude thoracic injuries. It was while in the first case, the patient was already symptomatic and the diagnosis of COVID-19 was confirmed in her before the diagnosis of pneumoperitoneum. In both cases, given that there was no perforation in the gastrointestinal tract and since the patients had no underlying disease other than COVID-19, the possibility of spontaneous pneumoperitoneum due to COVID-19 was raised.

Evidence from a previous study suggests that coronavirus is highly susceptible to the gastrointestinal tract (11). ACE2 is known as the target enzyme of

SARS-COV-2. The highest levels of this enzyme are found in the alveolar epithelium of lungs, small intestinal enterocytes, and vascular endothelium, suggesting that the abdominal viscera may be vulnerable to placement of the virus (7, 8, 12). Recent studies indicate that ACE2 is present not only in intestinal cells but also in the esophagus, stratified epithelial cells, and absorptive enterocytes from the ileum to the colon. Moreover, the expression of ACE2 in the small intestine, duodenum, and colon is about 100 times higher than that in the lungs (9, 12, 13). Accordingly, various studies showed that along with the respiratory system, the gastrointestinal tract can be considered as an alternative route of coronavirus infection (8, 12).

The incidence of symptoms such as diarrhea, nausea, vomiting, and abdominal discomfort vary considerably among different study populations (7, 12). Diagnosis of the virus has also been confirmed in intestinal and even fecal biopsies of the patients, which could account for intestinal complaints, potential recurrences, and fecal transmission. Based on the results of RNA fecal tests, the patients with intestinal symptoms appear to have a much higher percentage of intestinal virus, and therefore more are likely to be exposed to intestinal mucosal damage following contracting COVID-19 (7, 9).

COVID-19 can directly or indirectly damage the digestive system. In the direct damage of intestinal mucosa by enteropathic viruses, after activation of the inflammatory response, the reaction chain of viremia and inflammatory factors can damage the digestive system (14). During indirect damage, small vascular thrombosis and non-occlusive mesenteric ischemia can also occur secondary to virus infection (8). Moreover, the intestine acts as a large immune organ in the body, and the changes in the composition and function of gastrointestinal tract flora through common mucosal immune system affect the respiratory tract. Conversely, disorders of the normal flora of the respiratory tract can also affect the gastrointestinal tract through immune

regulation. This effect is referred to as the intestinal-pulmonary axis, and may explain why the patients with COVID-19 pneumonia also develop gastrointestinal problems (14). Common intestinal wall changes on CT scans of the patients with COVID-19 include thickening of the intestinal wall, pneumatosis, and presence of gas in the portal vein (8). In a study by Rajesh Bhayana et al., 34% of hospitalized patients had gastrointestinal complaints at the time of referral. They reported ischemic necrosis and fibrin thrombosis in the submucosal arterioles of the necrotic areas. In their study, pneumatosis was more common in the patients with mesenteric intestinal ischemia, which is more prevalent in the patients with COVID-19. Based on their results, other reasons suggested for pneumatosis include viral enteritis and intermittent positive pressure ventilation (8). In the present study, there were no symptoms of pneumatosis, vascular thrombosis and mesenteric ischemia in any of the cases. In direct observation of the first case, the only abnormal findings were dilatation of the loops from the descending colon to the sigmoid and small adhesions of hepatic flexure to the liver. Paraclinical studies performed for the second case showed no abnormal findings.

In the study of Rajesh Bhayana et al., out of four patients with pneumatosis after laparotomy, three cases of obvious intestinal infarction or ischemic mucosal necrosis were observed during laparotomy (8). In the present study, no symptoms of intestinal infarction or ischemic mucosal necrosis were seen, and there were not any clear observations other than pneumoperitoneum.

Studies by Lei Pan et al. (14) and Chaoqun Han et al., (9) showed that in the patients with gastrointestinal complaints, significantly longer time was elapsed from onset of symptoms to hospital admission than those without gastrointestinal complaints (9, 14). Their rationale for this finding was that the patients probably did not receive early diagnosis and treatment of COVID-

19, because they did not have typical respiratory complaints such as those observed in the respiratory of the patients (14). They also found that the progression of disease and increasing gastrointestinal complaints could indicate viral load and reproduction in the gastrointestinal tract, leading to more severe disease (7, 9, 14). Infiltration of the virus into the intestinal wall can lead to increased permeability of the intestinal wall and cause easier invasion of pathogens over a large intestinal tract as well as intestinal complaints like pneumatosis through reducing the function of intestinal barrier (8, 9). This phenomenon seems to be an answer to the question of how it is possible to see free gas inside the abdomen in the patients with COVID-19 without any other causes. In fact, increasing permeability of the intestinal wall and the occurrence of pneumatosis (8, 12) could account for gas leakage through the intestine wall into the abdominal cavity and occurring pneumoperitoneum.

## Conclusions

Surgical versus non-surgical management of the patients with pneumoperitoneum has always been considered a dilemma. In the COVID-19 patients, if pneumoperitoneum occurs in the absence of perforation and other causing agents, coronavirus-related intestinal damages can be considered as the causative factor through the mechanisms discussed. In this way, management of the patients through active monitoring and other conservative methods could be successful and avoid unnecessary surgery. However, there are several unrecognized things in this regard and further studies are needed.

## Acknowledgments

None.

## Conflicts of interest

The authors declare that they have no conflict of interest.

## Informed Consent

Informed consent was obtained from all the patients for being included in the study.

## Authors Contributions

MA, KM, JA and AY and FR is a main operator who performed the coronary intervention, and a primary author of manuscript development. MP, AKH, MS and AA collected background data, and provided significant authorship in the development of manuscript.

## References

1. Sebastian-Valverde E, Argudo-Aguirre N, Sancho-Insenser JJ. Is the conservative treatment the choice for the spontaneous pneumoperitoneum? *J Case Rep Imag Surg* 2015;1:5-8.
2. Pitiakoudis M, Zezos P, Oikonomou A, Kirmanidis M, Kouklakis G, Simopoulos C. Spontaneous idiopathic pneumoperitoneum presenting as an acute abdomen: a case report. *J Med Case Rep* 2011;5(1):86.
3. Mularski RA, Sippel JM, Osborne ML. Pneumoperitoneum: a review of nonsurgical causes. *Crit Care Med* 2000;28(7):2638-44.
4. Ahmed K, El Ghali Mohamed Amine AA, Jihene A, Khaoula M, Yamina H, Mohamed B. Airway management: induced tension pneumoperitoneum. *Pan Afr Med J* 2016;25.
5. Mann CM, Bhati CS, Gemmell D, Doyle P, Gupta V, Gorman DF. Spontaneous pneumoperitoneum: diagnostic and management difficulties. *Emerg Med Australas* 2010;22(6):568-70.
6. Tian Y, Rong L, Nian W, He Y. gastrointestinal features in COVID-19 and the possibility of faecal transmission. *Aliment Pharmacol Ther* 2020;51(9):843-51.
7. Cheung KS, Hung IF, Chan PP, Lung K, Tso E, Liu R, et al. Gastrointestinal manifestations of SARS-CoV-2 infection and virus load in fecal samples from the Hong Kong cohort and systematic review and meta-analysis. *Gastroenterology* 2020;159(1):81-95.
8. Bhayana R R, Som A, Li MD, Carey DE, Anderson MA, Blake MA, et al. Abdominal imaging findings in COVID-19: Preliminary observations. *Radiology* 2020;297(1):E207-15.
9. Han C, Duan C, Zhang S, Spiegel B, Shi H, Wang W, et al. Digestive symptoms in COVID-19 the patients with mild disease severity: Clinical presentation, stool viral RNA testing, and outcomes: Clinical presentation, stool viral RNA testing, and outcomes. *Am J Gastroenterol* 2020;115(6):916-23.
10. Eslick GD, Chalasani V, Salama AB. Idiopathic pneumoperitoneum. *Eur J Int Med* 2006;17(2):141-3.
11. Wong SH, Lui RN, Sung JJ. Covid-19 and the digestive system. *J Gastroenterol Hepatol* 2020;35(5):744-8.
12. Gu J, Han B, Wang J. COVID-19: gastrointestinal manifestations and potential fecal-oral transmission. *Gastroenterology* 2020;158(6):1518-9.
13. Li Z, Wu M, Guo J, Yao J, Liao X, Song S, et al. Caution on kidney dysfunctions of 2019-nCoV the patients. *MedRxiv* 2020 Jan 1.
14. Pan L, Mu M, Yang P, Sun Y, Wang R, Yan J, et al. Clinical characteristics of COVID-19 the patients with digestive symptoms in Hubei, China: a descriptive, cross-sectional, multicenter study. *Am J Gastroenterol* 2020;115.

Copyright © 2022 Studies in Medical Sciences

This is an open-access article distributed under the terms of the [Creative Commons Attribution-noncommercial 4.0 International License](https://creativecommons.org/licenses/by-nc/4.0/) which permits copy and redistribute the material just in noncommercial usages, as long as the original work is properly cited.