

Culture-negative Infective Endocarditis in an Afebrile Old Woman: A Case Report

Ramin Eskandari ¹, Sepideh Emami², Yousef Rezaei³

Received 21 February, 2020, Accepted for publication 19 June, 2020

Abstract

Infective endocarditis (IE) is an uncommon infectious disease involving both endocardium and heart valves, which is associated with a high rate of morbidity and mortality. The absence of classical signs/symptoms of IE leads to difficulties in diagnosis of this clinical entity. Being negative-culture and afebrile upon presentation have been reported in some case series.

Case Report: A 69-year-old Caucasian woman presented with fatigue, tachycardia, and mild swelling of the left-sided knee. About 4 months before the index admission, she had swelling and aching of the left-sided wrist which was improved. Then, she developed left-sided knee swelling and aching with a limited range of motion which was continued with a right-sided knee arthralgia. The limited range of motion and aching improved within 5-7 days spontaneously. All tests for the detection of brucellosis and rheumatologic diseases were negative. The transesophageal echocardiography revealed a fixed mass sizing 5×8 mm on aortic valve non-coronary cusp suspicious for vegetation in trans-gastric view. Blood cultures were negative at three times before the initiation of empirical antibiotic therapy. She was given an ampicillin-sulbactam regimen and the regimen continued for 3 weeks and she was discharged home on a co-amoxiclavate regimen. After a year, echocardiography revealed the resolution of vegetation.

Conclusions: The diagnosis of IE in elderly patients with unspecific signs and symptoms is of great importance in our daily practice. Timely detection and proper management of such cases can improve the outcomes of patients.

Keywords: Infective endocarditis, blood culture, fever

Address: Firoozgar Hospital, Tehran, Iran

Tel: +989143451652

Email: Eskandari.r@iums.ac.ir

Introduction

Infective endocarditis (IE) is an uncommon infectious disease involving both endocardium and heart valves, which is associated with a high rate of morbidity and mortality (1). The management of IE has changed

during the past decade, so that early surgical intervention in some cases has been advocated (2). In addition, the diagnosis of IE needs to incorporate clinical findings, multiple imaging, and laboratory modalities to reach a consensus.

¹ Assistant Professor of Cardiology, Department of Cardiology, Iran University of Medical Sciences, Tehran, Iran

² Assistant Professor of Cardiology, Department of Cardiology, Iran University of Medical, Tehran, Iran Sciences (Corresponding Author)

³ Rajaie Cardiovascular Medical and Research Center, Iran University of Medical Sciences, Tehran, Iran

The IE has a diverse nature that resulted in different presentations of disease in the population. The peak age of IE has changed during past decades from 45 years to 70 years (3). The absence of classical signs/symptoms of IE leads to difficulties in the diagnosis of this entity. Negative-culture and afebrile individual upon presentation have been reported in some case series; (4-6) however, the concomitant presentation of these classical signs is rare. In this report, we describe a 69-year-old Caucasian woman who presented with polyarthralgia and fatigue without fever and positive blood culture.

Case presentation

A 69-year-old woman presented to our clinic with fatigue, tachycardia, and mild swelling of the left-sided knee. She had a history of breast cancer that underwent a mastectomy 24 years ago and received six courses of chemotherapy. She also had a history of parathyroidectomy and thyroid lobectomy caused by nodular findings of 5 years ago. Other prior histories included diabetes mellitus, hypertension, and dyslipidemia. She was on medical therapy for these diseases. Upon presentation, her blood pressure was 125/70 mm Hg with an axillary temperature of 37.2° C. The heart and lung auscultations revealed normal sounds. All joints were free of swelling and tenderness, but her right-sided knee had a limited range of motion. There were no dermatologic findings at last presentation to our cardiology clinic. The electrocardiographic evaluation showed sinus tachycardia during hospitalization. About 4 months before the index admission, she had swelling and aching of left-sided

wrist which was improved. Then, she developed a left-sided knee swelling and aching with a limited range of motion which was continued with right-sided knee arthralgia. The limited range of motion and aching improved within 5-7 days spontaneously. She had mild proteinuria (2+ qualitative) in previous evaluations.

All tests for the detection of brucellosis were negative. Tests for rheumatologic diseases including rheumatic factor, anti-nuclear antibody, anti-double-stranded DNA, anti-cyclic citrullinated peptide were also in normal ranges. Only the erythrocyte sedimentation rate and C - reactive protein were elevated. The sonography of keen joint showed a mild effusion in supra-patellar space. The chest x-ray revealed normal findings. The patient underwent transthoracic echocardiography which revealed a left ventricular ejection fraction of 55% and a view suspecting for an increased thickness or small vegetation of aortic valve leaflet. Therefore, she underwent transesophageal echocardiography that demonstrated a fixed mass sizing 5×8 mm on aortic valve non-coronary cusp suspicious for vegetation in the trans-gastric view (Figure 1-A). Blood cultures were negative at three times before the initiation of empirical antibiotic therapy.

After consultation with an infectious disease specialist, the patient was given an ampicillin-sulbactam regimen. Her clinical status significantly improved after 4 days. This regimen continued for 3 weeks and she was discharged home on co-amoxiclave regimen. The patient underwent echocardiographic examination after 12 months, which revealed the resolution of mentioned vegetation on aortic valve leaflet (Figure 1-B).

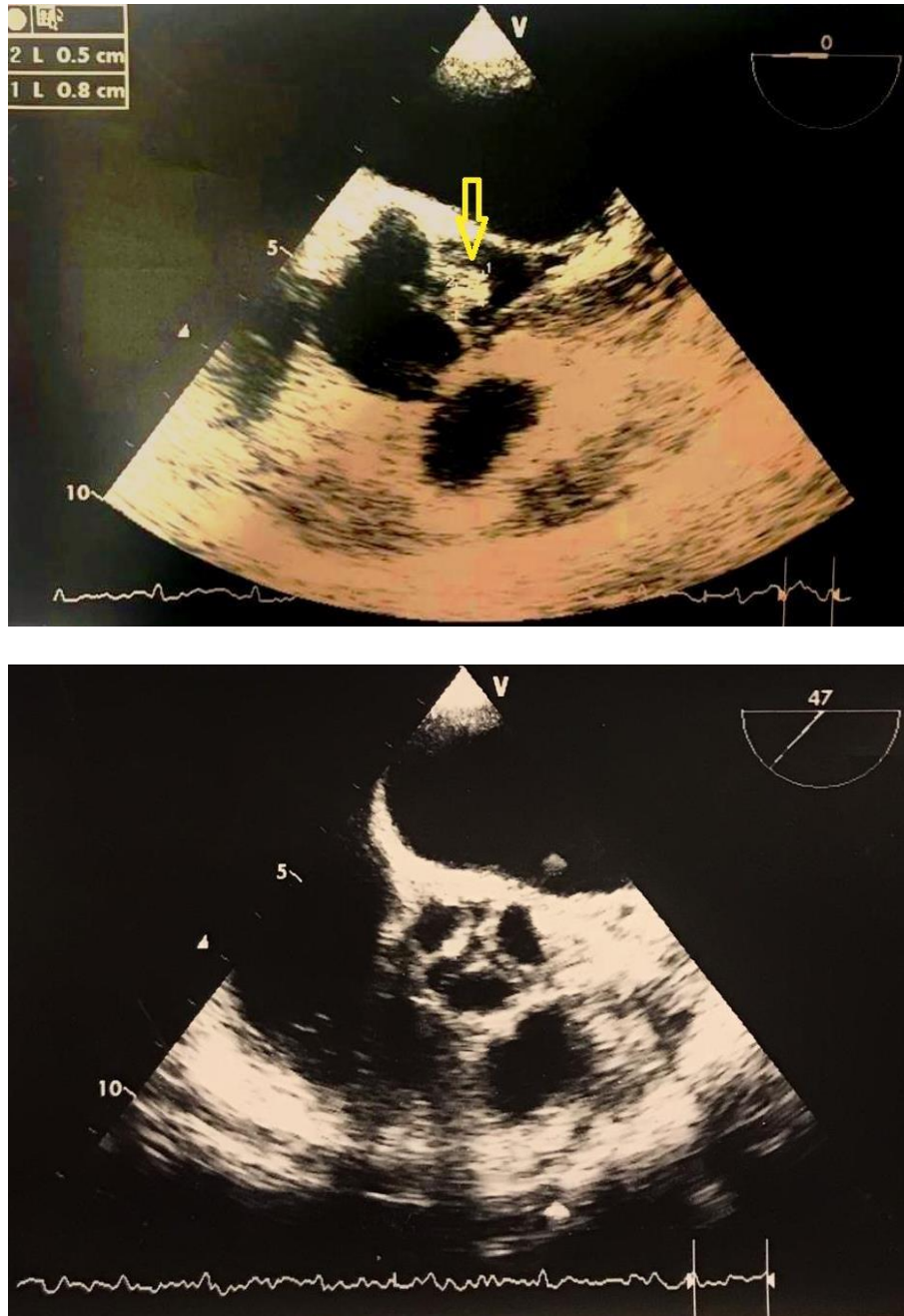


Figure 1- Picture showing (A) the vegetation on aortic valve and (B) the resolution after treatment

Discussion

The diagnosis of IE is based on clinical presentation and diagnostic modalities, including echocardiography and microbiologic assessments (7). On the other hand, the diagnosis of IE has remained as a challenging issue in cardiology practice because of the heterogeneity of presentation and rare pathogenesis (8). Since the emergence of Duke's criteria, it is a classical tool for the

diagnosis of IE; however, due to some shortcomings, it has been modified (9). Elderly individuals have a five-fold increased risk of IE compared to other adult population. The diagnosis of IE is difficult among elderly because of unusual presentations and concomitant systemic involvements that can lead to higher morbidity and mortality in such a vulnerable population.³

Several case series and international cohorts of IE found that the rate of culture-negative IE is accounted for about 10-21% of cases(4, 10-13), and afebrile cases are also observed in approximately 15% (4) and 22% (13) of patients with IE. The presence of fever and positive cultures in association with intracardiac mass on echocardiographic examination should raise the suspicion for IE; however, we should consider IE in culture-negative and afebrile patients with mass on echocardiography too,(14) since there is no proper tool to discriminate mass from thrombosis in patients with unusual clinical findings. Therefore, the high suspicion of IE should be kept mind, particularly, in the recent era which is associated with a higher risk of IE among old patients with unspecific presentations. In this study, we did not perform tissue sampling from the aortic valve and the polymerase chain reaction (PCR) test for identifying probable rare microorganisms that are culture-negative. Therefore, culture-negative cases should be further assessed using the PCR and surgery-related cases that will have tissue sampling for further evaluations (15).

In conclusion, the diagnosis of afebrile and culture-negative IE in elderly patients is of great importance in our daily practice, during which we encountered with higher rates of old patients with unspecific clinical features compared to prior decades. Timely detection and proper management of such cases can improve the outcomes of patients.

Conflicts of interest

The authors have none to declare.

References

1. Habib G, Lancellotti P, Antunes MJ, Bongiorni MG, Casalta JP, Del Zotti F, et al. 2015 ESC Guidelines for the management of infective endocarditis: The Task Force for the Management of Infective Endocarditis of the European Society of Cardiology (ESC). Endorsed by: European Association for Cardio-Thoracic Surgery (EACTS), the European Association of Nuclear Medicine (EANM). *Eur Heart J* 2015;36:3075-128.
2. Kang DH, Kim YJ, Kim SH, Sun BJ, Kim DH, Yun SC, et al. Early surgery versus conventional treatment for infective endocarditis. *N Engl J Med* 2012;366:2466-73.
3. Ursi MP, Durante Mangoni E, Rajani R, Hancock J, Chambers JB, Prendergast B. Infective Endocarditis in the Elderly: Diagnostic and Treatment Options. *Drugs Aging* 2019;36:115-24.
4. Gentry LO, Khoshdel A. New approaches to the diagnosis and treatment of infective endocarditis: review of 100 consecutive cases. *Texas Heart Institute journal* 1989;16:250-7.
5. Suh Y, Ja Kim M, Seung Jung J, Pil Chong Y, Hwan Kim C, Kang Y, et al. Afebrile Multi-valve Infective Endocarditis Caused by *Lactococcus garvieae*: A Case Report and Literature Review. *Intern Med* 2016;55:1011-5.
6. Tasher D, Raucher-Sternfeld A, Tamir A, Giladi M, Somekh E. *Bartonella quintana*, an Unrecognized Cause of Infective Endocarditis in Children in Ethiopia. *Emerg Infect Dis* 2017;23: 1246–52.
7. Hoen B, Duval X. Clinical practice. Infective endocarditis. *N Engl J Med* 2013;368:1425-33.
8. Medani S, O'Callaghan P. Rare manifestations of infective endocarditis: the long known, never to be forgotten diagnosis. *BMJ Case Rep* 2015;2015:bcr2015211276.
9. Li JS, Sexton DJ, Mick N, Nettles R, Fowler VG Jr, Ryan T, et al. Proposed modifications to the Duke criteria for the diagnosis of infective endocarditis. *Clin Infect Dis* 2000;30:633-8.

10. Houpi kian P, Raoult D. Blood culture-negative endocarditis in a reference center: etiologic diagnosis of 348 cases. *Medicine* 2005;84:162-73.
11. Lamas CC , Eykyn SJ. Blood culture negative endocarditis: analysis of 63 cases presenting over 25 years. *Heart (British Cardiac Society)* 2003;89:258-62.
12. Murdoch DR, Corey GR, Hoen B, Miro JM, Fowler VG Jr, Bayer AS, et al . Clinical presentation, etiology, and outcome of infective endocarditis in the 21st century: the International Collaboration on Endocarditis-Pro prospective Cohort Study. *Arch Intern Med* 2009;169:463-73.
13. Habib G, Erba PA, Iung B, Donal E, Cosyns B, Laroche C, et al. Clinical presentation, aetiology and outcome of infective endocarditis. Results of the ESC-EORP EURO-ENDO (European infective endocarditis) registry: a prospective cohort study. *Eur Heart J* 2019;40:3222-32.
14. Ionescu AA , Butchart EG. The vegetation that was not a vegetation: excusable misinterpretation of transesophageal echocardiography findings in late infective endocarditis of a prosthetic mitral valve. *J Am Soc Echocardiogr* 2000;13:322-4.
15. Rovey C, Greub G, Lepidi H, Casalta J-P, Habib G, Collart F, et al. PCR detection of bacteria on cardiac valves of patients with treated bacterial endocarditis. *J Clin Microbiol* 2005;43:163-7.