

## Automated differentiation of benign and malignant liver tumors by Ultrasound Images

Milad Zeinali Kermani<sup>1</sup>, Akbar Gharbali<sup>2\*</sup>

Received: 19 May, 2018; Accepted: 27 Aug, 2018

### Abstract

**Background & Aims:** Early detection and reliable differentiation of benign and malignant liver tumors could lead to improved cure rate and costs. Ultrasound image (US) is a convenient medical imaging method for interpreting liver tumors. Visual inspection of ultrasound images sometimes is combined with error and needs biopsy to confirm whether a tumor would be benign or malignant. The aim of this study is to explore the potential of computerize texture analysis methods for classifying benign and malignant liver tumors in US imaging.

**Methods and materials:** The US image database comprised 38 liver patients (25 malignant and 13 benign). Up to 270 texture features parameters as descriptors computed for each selected region of interest (ROIs) under default normalization scheme. Two feature reduction methods: Fisher and POE+ACC algorithms are applied to find the most effective features to differentiate benign from malignant liver. Obtained features parameters under two standardization states: standard (S) and nonstandard (NS) were used for texture analysis with PCA and LDA. Finally, Receiver Operating Characteristic (ROC) curve analysis was used via calculating sensitivity, specificity accuracy and Az value (area under the ROC curve) to examine the discrimination performance of applied texture analysis methods.

**Results:** The very excellent performance for discrimination between benign and malignant liver tumors was recorded for LDA with sensitivity of 98.7%, specificity of 100% and Az value of 1. Also, for PCA discrimination results has sensitivity of 98.6%, specificity of 100% and Az value of 0.99.

**Conclusion:** Our results indicates that texture analysis of the liver US images has potential to increase confidence of radiologist in classification of benign from malignant liver tumors.

**Keywords:** Texture Analysis, Liver tumors, Ultrasound image, sensitivity, specificity, Biopsy

**Address:** Medical Physics Department, faculty of medicine, Urmia University of Medical Sciences, Urmia, West Azerbaijan

**Tel:** (+98) 914-935-8500

**Email:** Gharbali@yahoo.com

### Introduction

The liver is the body's second largest organ that has many important functions, including clearing toxins

from the blood, metabolizing drugs, produce blood proteins and bile and etc (1). Liver tumor diseases are

<sup>1</sup> MSc graduated Student in Medical Physics, Medical Faculty, Urmia University of Medical Sciences, Urmia, Iran

<sup>2</sup> Medical Physics Department, Medical Faculty, Urmia University of Medical Sciences, Urmia, Iran (Corresponding Author)

one of important cause of morbidity and mortality in worldwide(2).

Ultrasound (US) is a useful tool for imaging of focal liver disease. US has some advantage such as: safety, relative accuracy, low cost and availability. That's the reasons why US is a prevalent imaging method (3). In US images the visual aspects of benign and malignant liver tumors are very similar in some cases. So, the diagnosis value of the ultrasound imaging is relatively low in this situation(4). Biopsy is the gold standard for detection of liver tumor's type (benign and malignant). But, it is an invasive procedure, with possible side-effects(5).

Computer Aided Diagnosis (CAD) systems are used to improve diagnosis value of US images in diffuse liver diseases (6). Texture is a visual concept and there is no mathematical definition for it. However, we can define texture as complex visual sub-patterns that have characteristic brightness, color, shape and size. This local sub-patterns are described by given coarseness, fineness, regularity, smoothness and etc (7). Texture analysis is a post processing method that characterizes regions of interest (ROI) in an image by spatial variations in pixel intensities (8).

Therefore, based on texture analysis of US images a non-invasive method has been used to help doctors, diagnose precisely and objectively. Accordingly, this study focused on investigation the potential of texture analysis algorithms for reliable classification of liver tumors.

## Materials and Methods

In agreement with the Iranian ministry of health ethical legislation on clinical trials, our study protocol has been approved by the research deputy of Urmia Medical Science University. The liver US images Databases consists of 38 patients (25 malignant (metastasis) and 13 benign (6 hemangioma and 7 adenoma)) tumor which were reported by radiologists

and proven by other examinations. One image per patient was loaded in MaZda software version 4.6 for computerize texture analysis. Regions of interests (ROIs) were defined in similar shape and size within the tumor sites of the liver US images. The ROIs excluded areas containing blood vessels and bile ducts (10). About 129 ROIs included 74 malignant, 55 benign were selected for classification. At the default schemes of gray level intensities of US images in pixel level, up to 270 texture features parameters per ROIs computed based on six statistical and structural features extraction methods: Image histogram, gray-level co-occurrence matrix (GLCM), Run Length Matrix (RLM), gradient, auto-regressive (AR) and wavelet transform (11). Table 1 represent six multi scale texture feature parameters computing methods used in this study. From the statistical point of view, it is not wisely all 270 extracted texture feature parameters to be use for texture analysis. So the features parameters eliminated to the ten features as a best and effective descriptor of difference between benign and malignant liver tumor (table 2). Feature reduction applied methods are: Fisher and POE+ACC. the Fisher algorithm is based on maximization of Fisher coefficient that is defined as a ratio of between-class variance to within-class variance. POE+ACC method is based on minimization of both classification error probability (POE) and average correlation coefficients (ACC) between chosen features (12,13, 14). Under two features standardization and non standardization state, two automatic texture features analysis programs were applied for discrimination defined ROIs from the US images of liver tumors. They involve PCA (principal component analysis) and LDA (linear discriminant analysis). The PCA also known as Karhunen- Loeve Transform (KLT) that attempt to reduce dimensionality of features data to find most expressive features (MEF). In Mazda software, MEF often has been computed and represented in one or multidimensional for graphical distribution analysis that help us to visualize the

separation of two ROIs categories, benign and malignant liver US images (14). The LDA has also known as class-based KLT, Fisher discriminant analysis that seeks for most discriminative features (MDF). Features obtained by LDA are useful for pattern classification since they make the data of the same class closer to each other, and the data of different class further away from each other (14). In Mazda software

MDF also is computed and represented in one or two dimensions to graphical visualization the separation of two ROIs categories, benign and malignant liver US images (14). Both PCA and LDA use linear transformation of the texture pattern.

The pre processed parameter vectors were classified with B11 (combined software with MaZda) by means of a 1-NN (first nearest neighbor) classifier (12).

**Table1:** Six multi scale Texture features extraction methods used by MaZda software for computing features parameters

Feature Extraction Methods	Histogram	Absolute gradient	Run-length matrix	Co-occurrence matrix	AR model	Wavelet transform
Features Parameters	Mean, Variance, Skewness, Kurtosis, Percentile1 %, Percentile10 %, Percentile50 %, Percentile90 %, Percentile99 %	Gradient, Mean, Variance, Skewness, Kurtosis, Nonzero	Run length non-uniformity, Grey level non-uniformity, Long run emphasis, Short run emphasis, Fraction of image in runs (for 4 angles (vertical, horizontal, 0° and 135°))	angular second moment, contrast correlation, sum of squares, inverse difference moment, sum average, sum variance, sum entropy, entropy, difference variance, difference entropy (for 4 angles (vertical, horizontal, 0° and 135°))	□□ □□ □□ □□ □	wavelet transform coefficients in sub bands LL, LH, HL, and HH

**Table2:** Summarizes the 10 best selected features parameters with maximum Fisher Coefficient and Minimum POE+ACC within each defined ROI in benign and malignant liver US images

ROI Normalization	Texture Features parameters selection algorithms			
	Fisher		POE+ACC	
	Feature Name	Value	Feature Name	Value
	Mean	12.3236	S(5,0)SumAverg	0.0000
	Perc.10%	12.2918	Perc.01%	0.2634

ROI Normalization ↓	Texture Features parameters selection algorithms			
	Fisher		POE+ACC	
Default	S(3,-3)SumAverg	12.2836	WavEnLL S-1	0.3338
	S(3,0)SumAverg	12.2803	Perc.10%	0.3790
	S(5,0)SumAverg	12.2766	S(5,5)SumAverg	0.4020
	S(2,0)SumAverg	12.2755	WavEnLH S-2	0.4145
	S(2,-2)SumAverg	12.2747	WavEnLL S-2	0.4166
	S(4,0)SumAverg	12.2746	S(4,4)SumAverg	0.4327
	S(4,-4)SumAverg	12.2411	S(4,0)SumAverg	0.4421
	S(1,0)SumAverg	12.2620	Perc.50%	0.4522

The discrimination performance of the applied computerize texture analysis methods evaluated by confuse matrix and ROC curve analysis via calculating sensitivity, specificity, accuracy and area under the ROC curve ( $A_z$  value) (15, 16). The stages of our study are summarized in Figure1.

$$\text{Accuracy} = (TP + TN) / (TP + TN + FN + FP)$$

$$\text{Sensitivity} = TP / (TP + FN)$$

$$\text{Specificity} = TN / (TN + FP)$$

TP = True positive, malignant tumor, classified as malignant.

TN = True negative, benign tumor, classified as benign.

FN = False negative, malignant but classified as benign

FP = False positive, benign but classified as malignant

Analysis of data and plotting ROC curve was performed by SPSS and Excel software.

## Results

In this study, about 270 parameters are extracted from each ROI at default normalization mode. We applied Fisher and POE+ACC algorithms for selection feature sets with 10 best features as a discriminator of benign and malignant liver tumors. Table 2 summarizes

the Fisher and POE+ACC selected features under default normalization scheme.

The PCA and LDA in combination of k-NN classifier were used for texture analysis. Figure 2 show the distribution of trained ROIs based on an example of selected features set via PCA and LDA analysis methods.

The discrimination performance of the applied texture analysis methods for different feature sets obtained under applied options were tested by ROC Curve analysis. Table3 represents discrimination performance results of the PCA texture analysis method under applied options.

The discrimination performance results affected by applied features standardization and features selection methods. In general, discrimination accuracy varied between 98.5% and 97.7% for PCA texture analysis method with 1-NN classifier The highest discrimination accuracy ( $A_z$  value) was obtained by default normalization for non-standard / standard Fisher' selected features which corresponded to a sensitivity of 96.7% and specificity of 98.2% and  $A_z$  value of 0.98 (table 3). From radiologist point of view, the confidence range for discrimination benign from malignant liver is excellent if the computerize PCA texture analysis has been used beside conventional view.

Table 4 represent discrimination performance results of the LDA texture analysis method under applied options. The sensitivity, specificity and area under the ROC curve (Az value) were nil for standardization, but effected by selection features methods. The highest discrimination accuracy was obtained by default-nonstandard Fisher parameters which corresponded to sensitivity of 98.7% and specificity of 100% and Az value of 0.99. In general, the A z value of the LDA texture analysis method with 1-NN classifier varied

between 0.96 to 0.99 that provide very excellence confidence for radiologist in discrimination benign from malignant liver when computer LDA texture analysis has been used (table 4).

For comparison, maximum discrimination performance results with PCA and LDA texture analysis methods represent in figure 3 in terms of ROC curve areas (Az values).

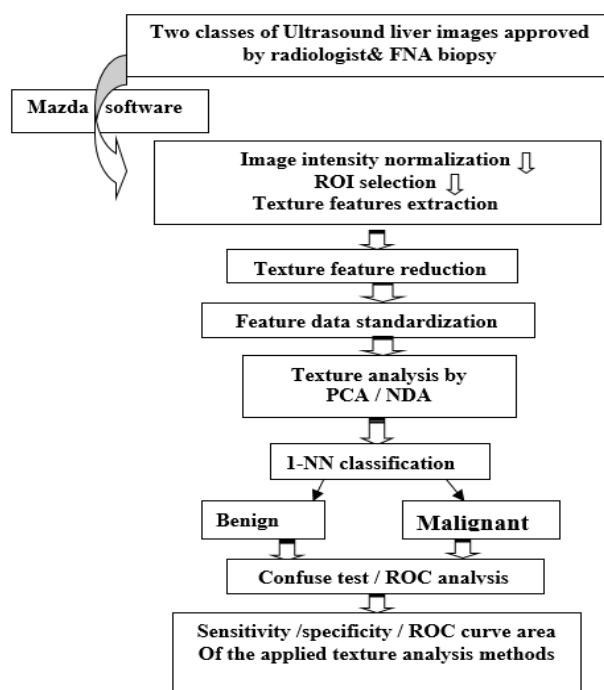


Fig 1. Schematic diagram of our scheme for computerize discrimination of benign from malignant liver tumor

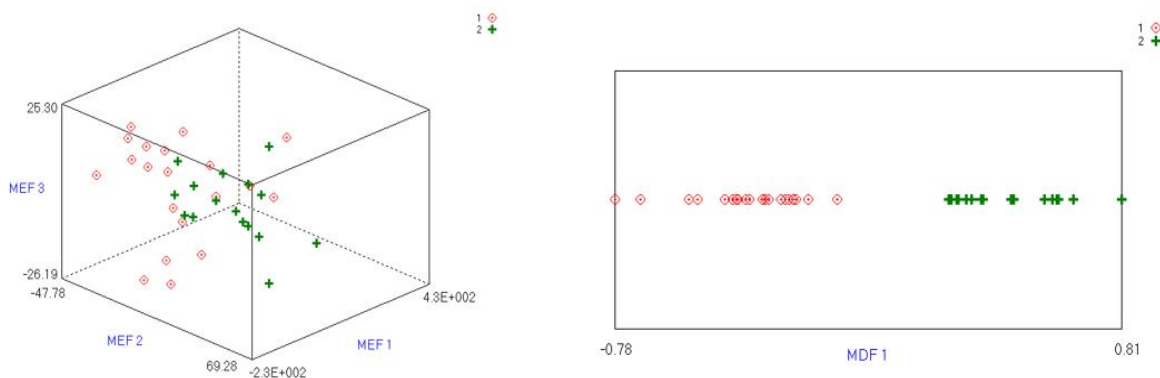


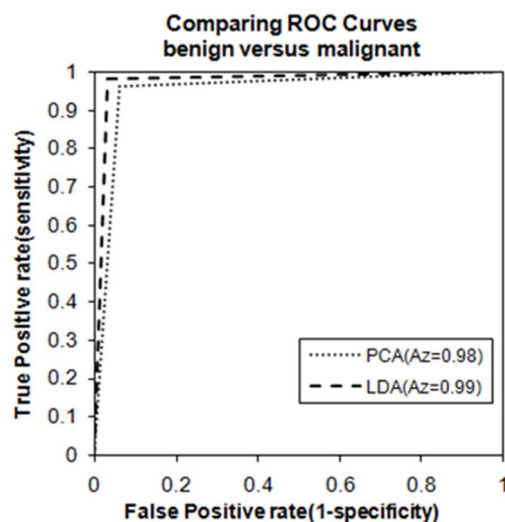
Fig 2. Illustrated graphical separation of ROIs from benign (No:1) versus malignant (No:2) liver tumors; (A) by PCA via the Most expressive features (MEF) and (B) by LDA via the Most discriminative features(MDF).

**Table 3.** Differentiation performance results of the PCA texture analysis for 4 different features sets under applied options.

Discrimination performance of Benign versus malignant liver							
Texture Analysis Method	Applied options			Sensitivity	Specificity	Accuracy	Az value
	ROI Normalization	Features Standardization	Features Selection				
PCA With k-NN classifier	Default	N.S.	Fisher	96.65	98.21	98.46	0.98
			POE+ACC	97.30	98.21	97.69	0.97
	S	S	Fisher	96.65	98.21	98.46	0.98
			POE+ACC	97.3	98.21	97.69	0.97

**Table 4.** Differentiation performance results of the LDA texture analysis for 4 different features sets under applied options

Discrimination Benign versus malignant liver							
Texture Analysis Method	Applied options			Sensitivity	Specificity	Accuracy	Az value
	ROI normalization	Features Standardization	Features Selection				
LDA With 1-NN classifier	Default	N.S.	Fisher	98.7	100	99.2	0.99
			POE+ACC	97.3	96.4	96.9	0.96
	S	S	Fisher	98.7	100	99.2	0.99
			POE+ACC	97.3	96.4	96.9	0.96



**Fig 3.** Shows to ROC curves plotted on the same graph for discrimination of benign and malignant liver tumor with maximum accuracy by LDA and PCA texture analysis

In applied radiology, automatic classification of liver tumors has been under active study for over recent decades. Mala et al. (2006) employed CT liver images in order to classification of benign and malignant liver tumors. They combined biorthogonal wavelet transform with Linear Vector Quantization (LVQ) neural network for classification of tumors. Results show that the LVQ neural network with 0.01 learning rate, 20 hidden neurons and 100 epochs can be used to classify malignant and benign tumor with an accuracy of 92% sensitivity of 98% and specificity of 85% (17). Yoshida et al. (2003) used wavelet transforms in order to discriminate benign (hemangiomas) and malignant liver tumors (Hepatocellular carcinomas (HCCs) and metastasis) in ultrasound images. 193 regions of interest (ROIs) were manually extracted from within the focal liver lesions. Multiscale texture features based wavelet transforms were calculated from each ROI and classification was performed by an artificial neural network (ANN). ROC analysis of data represent a high AUC value of 0.92 in distinguishing benign and malignant lesions, 0.93 in distinguishing hemangioma from HCCs and 0.94 in distinguishing hemangiomas from metastases (3). Pavlopoulos et al. (2000) applied Fuzzy Neural Network (FNN) to characterize diffused liver diseases. The result of this study showed up to 82.67% classification accuracy (18). Balasubramanian et al. used texture analysis methods for classification of benign, malignant, cyst and normal liver images. For this purpose they used texture features based on SGLDM, RUNL, TEM and Gabor wavelets. Eight features were selected manually and also Principle Component Analysis (PCA) is used to extract the principal features. PCA based features were used by K-means clustering algorithm, whereas manually selected features were classified by BPN. The results show that classification accuracy by BPN (75% to 93.5%) were better result than K-means(70%-88%) (19). Chen et al designed an automatic system for classification of liver

tumors into hepatoma and hemageoma by CT images. Fractal features and (SGLCM) -based feature was selected. Classification was performed by a modified probabilistic neural network (PNN) classifier. Accuracy of 83%, was reported on a set of 20 HCCs and 10 hemangioma (20).

In general, our study results for differentiation benign versus malignant live US images represent a superior accuracy and therefore the area under the ROC cure analysis. The same as most researchers, we believe that LDA methods has better results than PCA.

## Discussion

Even though, the number of patient with liver tumors in this work was small but more ROIs were examined. It has shown that automated texture analysis with such a high discrimination performance has high potential to highlight difference on benign and malignant texture patterns in liver US image and thus to help radiologist as a complementary tool in evaluation liver patients.

## Acknowledgments

This study designed by Dr. Akbar Gharbali as a research work toward Master Degree. It has been approved by ethical committee and supported financially by the research

Bureau of the Urmia Medical Science University.

I would like to thank sincerely Dr. Afshin Mohamadi (radiologist) for digital liver ultrasound images support.

## References

- 1- Kiernan F. The anatomy and physiology of the liver. *Philos. Trans* 1833;711.
- 2- Herszenyi L, Tulassay Z. Epidemiology of gastrointestinal and liver tumors. *Eur Rev Med Pharmacol Sci* 2010;14(4):249-58.
- 3- Yoshida H, Casalino DD, Keserci B, Coskun A, Ozturk O, Savranlar A. Wavelet-packet-based texture analysis for differentiation between benign and malignant liver

- tumours in ultrasound images. *Phys Med Biol* 2003;48(22):3735.
- 4- Poonguzhali S, Deepalakshmi B, Ravindran G, editors. Optimal feature selection and automatic classification of abnormal masses in ultrasound liver images. *Signal Processing, Communications and Networking, 2007 ICSCN'07 International Conference on; 2007: IEEE.*
  - 5- Goceri E, Shah ZK, Layman R, Jiang X, Gurcan MN. Quantification of liver fat: A comprehensive review. *Comput Biol Med* 2016;71:174-89.
  - 6- Vicas C, Nedeveschi S, Lupsor M, Badea R, Stefanescu H. Fibrosis detection from ultrasound imaging. The influence of necro-inflammatory activity and steatosis over the detection rates. *J Auto Comput Appl Mathematics* 2007;16(3):27-33.
  - 7- Materka A, Strzelecki M. Texture analysis methods—a review. Technical university of Lodz, institute of electronics, COST B11 report, Brussels; 1998. P.9-11.
  - 8- Simpson AL, Adams LB, Allen PJ, D'Angelica MI, DeMatteo RP, Fong Y, et al. Texture analysis of preoperative CT images for prediction of postoperative hepatic insufficiency: a preliminary study. *J Am Coll Surg* 2015;220(3):339-46.
  - 9-Szczypiński PM, Strzelecki M, Materka A, Klepaczko A. MaZda—a software package for image texture analysis. *Comput Methods Programs Biomed* 2009;94(1):66-76.
  - 10-Jirak D, Dezortová M, Taimr P, Hájek M. Texture analysis of human liver. *J Magn Reson Imaging* 2002;15(1):68-74.
  - 11-Hájek M. Texture analysis for magnetic resonance imaging: *Texture Analysis Magn Resona; 2006.*
  - 12-Materka A, Szczypinski P. MaZda user's manual. Adres: [www.elel.p.lodz.pl/programy/mazda/download/mazda\\_manual.pdf](http://www.elel.p.lodz.pl/programy/mazda/download/mazda_manual.pdf) [cytowany 18 września 2014 r]. 2002.
  - 13-Mucciardi AN, Gose EE. A comparison of seven techniques for choosing subsets of pattern recognition properties. *IEEE Trans Comput* 1971;100(9):1023-31.
  - 14-Dash M, Liu H. Feature selection for classification. : *Intell Data Anal* 1997;1(1-4):131-56.
  - 15-Metz CE. ROC methodology in radiologic imaging. *Invest Radiol* 1986;21(9):720-33.
  - 16-Metz CE. ROC analysis in medical imaging: a tutorial review of the literature. *Radiol Phys Technol* 2008;1(1):2-12.
  - 17- Mala K, Sadasivam V. Wavelet based texture analysis of Liver tumor from Computed Tomography images for characterization using Linear Vector Quantization Neural Network. *Advanced Computing and Communications, 2006 ADCOM 2006 International Conference on IEEE; 2006. p. 267–270.*
  - 18- Pavlopoulos S, Kyriacou E, Koutsouris D, Blekas K, Stafylopatis A, Zoumpoulis P. Fuzzy neural network-based texture analysis of ultrasonic images. *IEEE Eng Med Biol Mag* 2000;19(1):39-47.
  - 19- Balasubramanian D, Srinivasan P, Gurupatham R. Automatic classification of focal lesions in ultrasound liver images using principal component analysis and neural networks. *Engineering in Medicine and Biology Society, 2007 EMBS 2007 29th Annual International Conference of the IEEE IEEE; 2007. p. 2134–2137.*
  - 20- Chen E-L, Chung P-C, Chen C-L, Tsai H-M, Chang C-I. An automatic diagnostic system for CT liver image classification. *IEEE Trans Biomed Eng* 1998;45(6):783-94.
  - 21- Martínez AM, Kak AC. Pca versus lda. *IEEE Trans Pattern Anal Mach Intell* 2001;23(2):228-33.