

## Evaluation of Silymarin effects on post-operative peritoneal adhesion in Rats

Sara Javanmardi<sup>1</sup>, Samira Golmohammadi<sup>2</sup>, Ramin Mazaheri-khamene<sup>3</sup>

Received: 14 May, 2017; Accepted: 16 Jul, 2017

### Abstract

**Background & aims:** Adhesion and fibrotic bands formation is one of the most important post-surgical complication in pelvic and abdominal surgeries. Major studies in prevention of adhesion formation have based on antioxidant and anti-inflammatory agents. Silymarin, *Silybum marianum* extract contains compounds with antioxidant, anti-inflammatory and fibrinolytic activities thus could reduce adhesion formation. The aim of the present study was to examine silymarin effects on post-operative peritoneal adhesion prevention in rats.

**Materials & Methods:** In this study eighteen 8-week-old male Sprague-Dawley rats were used. Under general anesthesia a 2-3 cm ventral midline incision was aseptically made. To induction of adhesions the cecal abrasion model was used. Rats were randomly divided into three groups silymarin, vehicle and the control, each containing 6 rats. Rats in silymarin group received 50 mg/kg silymarin, while rats in the control group were given 0.9% sodium chloride and the vehicle group were treated with equal volume of poly ethylene glycol, intraperitoneally once daily for five days. All animals were sacrificed on the 15<sup>th</sup> postoperative day. The adhesions were scored as 0, 1, 2 and 3. The cecum and adherent bands were prepared for histopathological evaluation. A semi-quantitative scoring system of the histopathological grading scale was used for the evaluation of the inflammation grade.

**Results:** There were no incisional hernias or wound dehiscences in any animals of the three groups. Both macroscopic adhesion scoring and the histopathological grading showed significantly low adhesion scores in the silymarin group in comparison to the control group. ( $p < 0.05$ )

**Conclusion:** Based on results, it was concluded that silymarin is effective in preventing postoperative peritoneal adhesions in rats.

**Key words:** Silymarin, Post-operative peritoneal adhesion, Rats

**Address:** Department of Clinical Sciences, faculty of Veterinary Medicine, Tabriz University, Tabriz, Iran

**Tel:** +989144091128

**Email:** Sarahjavanmardi@yahoo.com

### Introduction

Formation of intra-peritoneal adhesions is the most common and serious complication after abdominal and pelvic surgery. Intra-peritoneal adhesions can cause complications such as abdominal or pelvic regions pains, intestinal obstructions, volvulus and female

infertility (1, 2). It has been postulated that reactive oxygen species (ROS) are involved in adhesion development following intra-abdominal surgery (3). After surgery, an increase in free radical activity, such as superoxide anions, xanthine oxidase and MDA levels, has been detected. Free radicals play a major role in

<sup>1</sup> Department of Clinical Sciences, faculty of Veterinary Medicine, Tabriz University, Tabriz, Iran (Corresponding author)

<sup>2</sup> Graduated Veterinary Medicine, University of Tabriz, Tabriz, Iran

<sup>3</sup> Department of Clinical Sciences, Faculty of Veterinary Medicine, Urmia University, Urmia, Iran

peritoneal adhesion formation following intra-abdominal surgery (4). A wide variety of approaches have been demonstrated in animal models and clinical practice to reduce or prevent adhesions by using anti-adhesion materials such as fibrinolytics, anti-inflammatory agents, antioxidants, anticoagulants, antibiotics and a number of materials that create a physical barrier (5,6,7,8) Major studies in prevention of adhesion formation have based on antioxidant and anti-inflammatory agents (7). Some studies showed that, plants have rich source of phenolic compounds, carotenoids, vitamins and terpenoids. These compounds have a potential antioxidants, anti-inflammatory and antineoplastic activities (9, 10). Milk thistle [*Silybum marianum* (*S.marianum*)] is a medical plant. Its extract is made of from seeds. The extract consists of about 65-80% silymarin (a flavonolignan complex) and 20-35% fatty acids, including linoleic acid. Silymarin is a complex mixture of polyphenolic molecules, including seven closely related flavonolignan (silybin A, silybinB, isosilybin A, isosilybin B, silychristin, isosilychristin, silydianin) and one flavonoid (taxofolin) (11,12). Silymarin, which is the most active component, is largely responsible for the pharmacological effects of this plants, including antioxidant, hepatoprotectant, anti-inflammatory agent, antibacterial, anti-allergic, antiviral, antineoplastic effects and fibrinolytic effects (12,13). Studies have reported that natural antioxidant substance reduces oxidative stress and has beneficial effects in prevention of intra-abdominal adhesion formation (1, 3). Flavonoids like silymarin are known to possess potent antioxidant and free-radical scavenging activities (13,14,15). Due to these aforementioned effects, we hypothesize that, silymarin might be useful as a preventive agent in post-surgical adhesions.

## Materials and Methods

### Animals:

Eighteen male Sprague-Dawley rats (200-250g) were individually housed in stainless steel cages under standard conditions and given food (commercial rat pellet) and water ad libitum. Rats were adapted to handling in the period prior to surgery. The experimental procedure and animal care were approved by the Ethics Committee of University of Tabriz.

### Experimental design:

A total 18 rats were randomly divided into three experimental groups of equal number.

### Chemicals:

Silymarin (Sigma-Aldrich, .S0292-50G,Italy) and Polyethylene glycol (PEG, Sigma-Aldrich, St.Louis, MO, USA).

### Surgical procedure:

The animals were fasted the night before surgery and then anesthetized with an intramuscular injection of 80 mg/kg of Ketamine5% (Alfasan, Woerden, Netherlands) and 10 mg/kg Xylazine 2% (Alfasan, Woerden, Netherlands). The abdomen was shaved; antisepsis was provided with povidone iodine. With a 2-3 cm ventral midline incision, the peritoneal cavity was entered. The cecum and terminal ileum were found and placed on a damp gauze pad. To form adhesions, the cecal abrasion model was used. Cecum was abraded with a sterile sponge on the antimesenteric side until petechial hemorrhage foci were observed (16). The abdominal incision was close in two layers with simple, continuous suture of nanabsorbable 3-0. Rats were randomly divided into three groups each contained 6 rats. Rats in silymarin group received 50 mg/kg Silymarin (17), while rats in the control group were given 0.9% sodium chloride (1ml) and the vehicle group was treated with equal volume of Poly ethylene glycol, intraperitoneally once daily for five days. On the 15<sup>th</sup> day of the study all the animals were euthanized with an overdose intraperitoneal injection of sodium thiopental with an overdose intraperitoneal injection of sodium thiopental (Trittau, Germany). In view of clinical

evaluation of possible adhesions, the peritoneal cavity was re-entered through an "inverse U" incision. The peritoneal adhesions were assessed on a 0, 1, 2 and 3 scale according to Evans et al.'s (Table 1), (18). The cecum and adherent bands were then sent for histopathological evaluation. The samples were histopathologically examined under light microscopy. A semiquantitative scoring system of the histopathological grading scale of Zühlke was used for the evaluation of the inflammation. Grade I was defined as weak connective tissue, rich cells, old and new fibrin and thin reticular fibers, grade II was defined as connective tissue with cells and capillaries, and few collagen fibers, grade III was characterized by firmer connective tissue, fewer cells, more vessels and few elastic and smooth-muscle fiber and grade IV was determined by old, firm granulation tissue which was cell poor and serosal layers which were hardly distinguishable (19).

#### Statistical analysis:

All statistical analysis was performed using Graph Pad Prism, Version 5.05 statistical software for windows. A nonparametric test, Kruskal-Wallis was

used to compare from the groups. A p value less than 0.05 was considered significant.

#### Results

There were no incisional hernias, wound infection or wound dehiscence present and none of the rats were expired during the study period.

#### Macroscopic adhesion scores:

Our evaluation of macroscopic adhesion intensity showed statistically significant differences between the groups ( $P < 0.05$ ). The adhesion scores for each group are shown in Table 2. and Figures 1-4.

#### Histopathological results:

The Zühlke scores were significantly lower in the silymarin (median=1) and vehicle (median=2) groups compared to the control group (median=3.5);  $P=0.005$ , (Figure 5). There were 3 animals in the control group with a Zühlke grade 4 score whilst the other groups had no animals with a grade 4 score. Three animals in the silymarin group had grade 1 and the others had grade 2 scores. Three animals in the vehicle group had grade 3, two animals had grade 2 and one of them had grade 1 score (Figure 6).

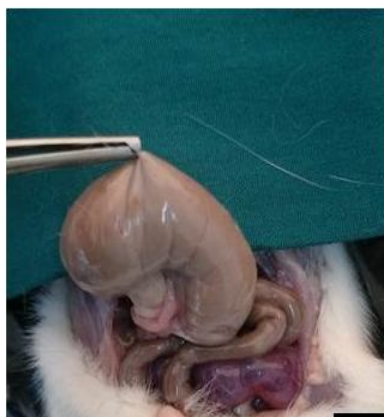

Fig.1. Score 0 adhesion

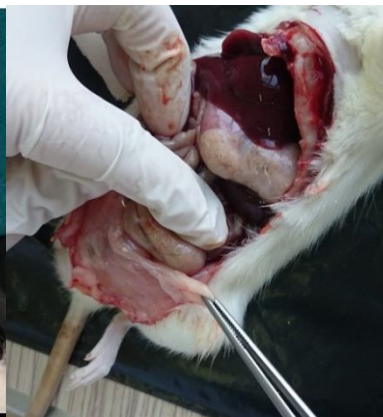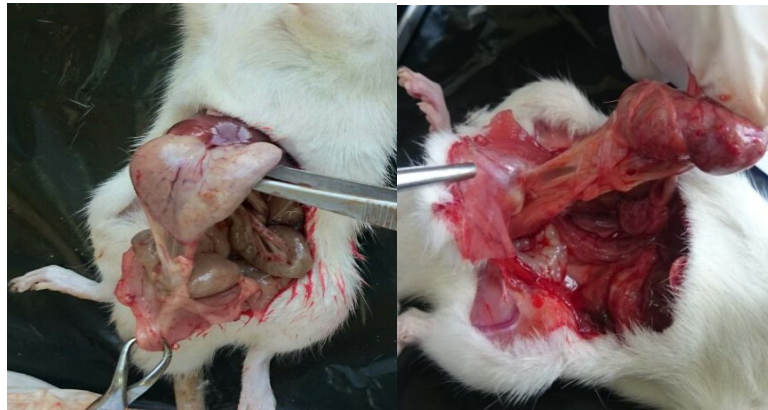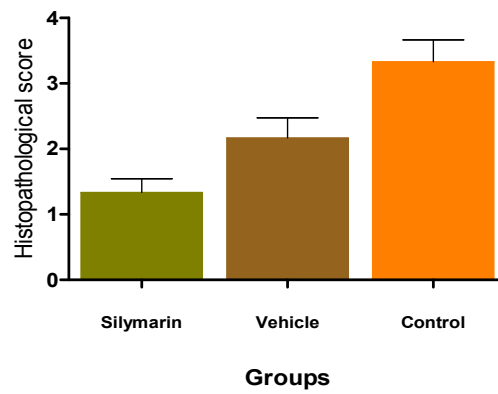


Fig.2. Score 1 adhesion

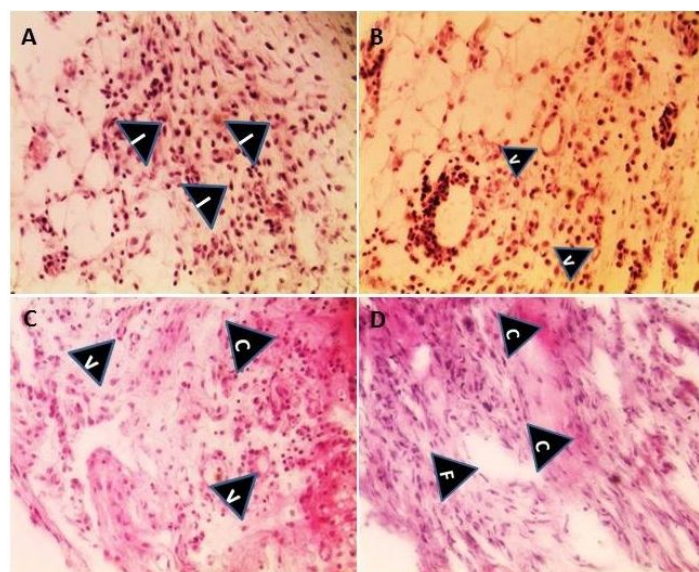


**Fig 3:** Score 2 adhesion

**Fig 4:** Score 3 adhesion



**Fig 5:** The histopathological scores in each group: those of the silymarin group were significantly lower than those of the control group ( $p < 0.05$ ).



**Fig 6:** Histopathological Grade according to the microscopic classification of Zuhlke. A) grade 1, B) Grade 2, C) Grade 3 and D) Grade 4 . H& E stain. Original magnification  $\times 400$ . I: Inflammatory cells, V: Vessel, F: Fibroblast, C: Collagen

**Table 1:** Evans adhesion scoring.

Score	Description
0	No adhesions
1	Spontaneously separating
2	Separation of adhesion with Traction
4	Separation of adhesion with a sharp dissection

**Table 2:** Distribution of adhesion scores

Score	Silymarin group	Vehicle group	Control group
0	2	0	0
1	3	2	0
2	1	4	2
4	0	0	4

Data are either number (n = 6 in each group)

Significant differences ( $p < 0.05$ ) were found for the adhesion

scores between the Silymarin and control groups.

## Discussion

Both macroscopic adhesion scoring and the histopathological grading showed significantly low adhesion scores in the silymarin group in comparison to the control group ( $p < 0.05$ ). Hence, the present study showed that silymarin effectively decreased the experimental postoperative abdominal adhesion rate. In the surgical area a local hypoxic environment occurs and leads to an ischemia/reperfusion process with a resultant increase in the levels of free radicals production (20). Inflammation and ischemia/reperfusion injuries are the internally generated sources of free radicals in the body (21). Tissue trauma in the peritoneal and pelvic cavities following surgery severely damage living cells by activating inflammatory responses and lead to generate free radicals. Overproduction of free radicals can cause oxidative damage to peritoneal mesothelial cells,

eventually leading to intra-abdominal adhesions formation. Prevention of adhesion formation after the restoration of anti-oxidative enzymes, such as catalase, superoxide dismutase and dimethyl sulfoxide has been observed in many studies (4,21). Rats treated with the antioxidants such as melatonin, green tea, curcumin and Vitamin E have shown significantly reduced severity of adhesions after abdominal surgeries (22,23,24,25). Eventually, antioxidant therapy is vital in scavenging free radicals and ROS preventing mesothelial cells degeneration in post-oxidative stress scenario (4). To date, herbal products are widely available to consumers and have become increasingly popular throughout the world. Milk thistle (Silymarin) is a popular natural choice that is consumed as herbal teas. Its extract is made from the seeds. Previous studies have shown the antioxidant and anti-inflammatory activities of silymarin. (11, 26). Increase in tissue catalase, glutathione and glutathione peroxidase values following silymarin treatment have been attributed to the inhibition of free radicals and lipid peroxidation (27,28). The results of the present study showed significant decrease in adhesion formation and severity in silymarin treated group compared to the control group ( $p < 0.05$ ). This reduction may be due to scavenging the free radicals as a result of the antioxidant effect of silymarin. The results of this study are consistent with previous studies using natural antioxidant agents prevent intraperitoneal adhesion formation (23,24). This data suggest that antioxidant agents may play a role in the prevention of intra-abdominal adhesion formation. Fibrinolysis process occurs in the first few days after peritoneal injury and lead to prevent adhesion formation during healing of the peritoneum. The early fibrinolytic activity plays an important role in the formation of peritoneal adhesions following abdominal surgery (29). Inflammatory mediators may augment peritoneal injury

in part by the release of oxidants and vasoactive agents. Evidence shows that certain mediators, such as transforming growth factors (TGF), vascular endothelial growth factors (VEGF) and interleukins decrease the fibrinolytic capacity of the peritoneum and increase the formation of the adhesions (30). Transforming growth factor-beta (TGF- $\beta$ ) is an important factor in regulating the inflammatory reaction and the production of extracellular matrix. These two processes are linked in the formation of fibrous adhesions after abdominal surgery. When the peritoneum is injured a fibrin strand is produced which is populated first by inflammatory cells then by fibroblasts which secrete extracellular matrix forming a permanent adhesion. TGF- $\beta$  promotes both chemotaxis of monocytes and the production of extracellular matrix by fibroblasts (31). Willimas RS et al. demonstrated that application of TGF- $\beta$ 1 to surgical adhesions resulted in increasing of the adhesions compared with controls not given TGF- $\beta$ 1 (28). Another study has reported that formation of abdominal adhesion is inhibited by anti TGF- $\beta$ 1 (29). Silymarin has been shown to increase fibrinolytic activity through the suppresses expression of profibrogenic procollagen via down-regulation of TGF- $\beta$ 1 mRNA in rats with biliary and hepatic fibrosis (32,33,34). VEGF is a potent angiogenic cytokine and has been proven to play a major role in early inflammatory responses. VEGF, recently found to be expressed by mast cells, and has important effects on several crucial mechanisms in formation of adhesions (35). Therefore, anti-VEGF monoclonal antibodies have been suggested for anti-adhesion agent. Intra-abdominal administration of bevacizumab a recombinant humanized monoclonal antibody that binds to and inhibits the biological activity of human VEGF, reduced the peritoneal adhesions severity in rats (36). Many studies have proven COX-2 enzyme plays an important role in the regulation of inflammatory and VEGF-mediated angiogenesis stages of postoperative adhesions development (37, 38). Silymarin suppress

both COX-2 expression and angiogenesis induced by VEGF (35,39,40). These findings may provide an understanding of the beneficial effects of silymarin in condition such as inflammation and oxidative stress. We did not measure the levels of expression of TGF- $\beta$ 1 and VEGF in this study; hence, there is a need for more research to be done on silymarin treatment given to prevent post-operative adhesions. In summary, and in agreement with previous studies, our results allow us to draw the conclusion that silymarin would protect the mesothelial cells against inflammatory and oxidative injury during peritoneal healing period. And diminish the formation of adhesion. The protective effect of silymarin is associated with its antioxidant, anti-inflammatory and antifibrotic properties, as it possibly acts as a free-radical scavenger.

### **Conclusion**

The present study shows that silymarin appeared to be safe and effective in the prevention of postoperative intra-abdominal adhesion formation in the experimental adhesion model of rat. Due to the nontoxic nature of silymarin, we suggest that it could be used for the prevention of peritoneal adhesion formation.

### **Acknowledgement:**

This study is for DVM thesis at Tabriz Veterinary Medicine Faculty. Authors would like to acknowledge authors would like to acknowledge University of Tabriz for financial support of this study.

### **Conflict of interest:**

The authors declare that there is no conflict of interest in this study.

### **References**

- 1-Ellis H. The cause and prevention of postoperative intraperitoneal adhesions. *Surg Gynecol Obstet* 1971; 133(3):497-511.

- 2-Diamond MP, Freeman ML. Clinical implications of postsurgical adhesions. *Hum Reprod Update* 2001; 7:567-76.
- 3-Allison H, Michael M, James Shapiro AM. Intra-abdominal adhesions: Cellular mechanisms and strategies for prevention. *Int J Surg* 2011; 9:589-94.
- 4-Snder T, Petrousjka T, Wim S, Casper HJ, Hans J. The role of neutrophils and oxygen free radicals in post-operative adhesions. *J Surg Res* 2006; 136:45-52.
- 5-DeCherney AH, Dizerga GS. Clinical problem of intraperitoneal postsurgical adhesion formation following general surgery and the use of adhesion prevention barriers. *Surg Clin North Am* 1997; 671: 77-88.
- 6-Arons CB, Cohen PA, Grower A, Reed KL, Leeman SE, Stucchi AF et al. Statins (HMG-CoA reductase inhibitors) decrease postoperative adhesions by increasing peritoneal fibrinolytic activity. *Ann Surg* 2007; 245:176-84.
- 7-Hosseini SV, Mehrabani D, Tavakolian AR, Tanideh N. Role of an anti-inflammatory drug in prevention of intraabdominal adhesions: An experimental study on Guinea pigs. *J Appl Anim Res* 2004; 26:123-5.
- 8-Shokouhi F, Farshid AA, Saifzadeh S, Javanmardi S. Evaluation of topical application of honey in prevention of post-operative peritoneal adhesion formation in dogs. *Iran J Vet Res* 2006; 7:59-62.
- 9-Yizhong C, Qiong L, Mei S, Harold C. Antioxidant activity and phenolic compounds of 112 traditional Chinese medicinal plants associated with anticancer. *Life Sci* 2004; 74:2157-84.
- 10-Shashi A, Sanjay K, Amita V, Mayank K, Alok M, Monika S. Herbal antioxidant in clinical practice: A review. *Asian Pac J Trop Biomed* 2014; 4:78-84.
- 11- Surai PF. Silymarin as a natural antioxidant: An overview of the current evidence and perspectives. *Antioxidants* 2015; 4:204-47.
- 12-Gupta OP, Sing S, Bani S, Sharma N, Malhotra S, Gupta BD et al. Anti-inflammatory and anti-arthritis activities of Silymarin acting through inhibition of 5-lipoxygenase. *Phytomedicine* 2000; 7:21-4.
- 13-Jiang C, Agawal R, Junxuan L. Anti-angiogenic potential of a cancer chemopreventive flavonoid antioxidant, Silymarin: Inhibition of key attributes of vascular endothelial cells and angiogenic cytokine secretion by cancer epithelial cells. *Biochem Biophys Res Commun* 2000; 276:371-8.
- 14-Mourelle M, Muriel P, Favari L, Franco T. Prevention of CCl4-induced liver by silymarin. *Fundam Clin Pharmacol* 1989; 3:183-91.
- 15-Ferenci P, Dragosics B, Dittrich H, Frank H, Benda L, Lochs H, et al. Randomized controlled trial of silymarin treatment in patients with cirrhosis of the liver. *J Hepatol* 1989; 9:105-13.
- 16-Oncel M, Kurt N, Remzi FH, Sensu SS, Vural S, Gezen CF et al. The effectiveness of systemic antibiotics in preventing postoperative intra-abdominal adhesion in an animal model. *J Surg Res* 2001; 101:52-5.
- 17-Manohar N, Manodeep C, Riyaz A, Shahzad H, Mohammed A. Investigation of nephroprotective effect of silymarin against methotrexate and ifosfamide induced toxicity in rats. *JPSR* 2015;6:174-9.
- 18-Evans DM, McAree K, Guyton DP, Hawkins N, Stakleff K. Dose dependency and wound healing aspects of the tissue plasminogen activator in the prevention of intraabdominal adhesions. *Am J Surg* 1993; 165:229-32.
- 19-Turkoglu a, Gul M, Yuksel HK, Alabalik U, Ulger BV, Uslukaya O, et al. Effect of intraperitoneal curcumin instillation on postoperative peritoneal adhesions. *J Med Princ Pract* 2015; 24:153-58.
- 20-Kurus S, Bozkirli OB, Barlas A, Duymus MA, Senes M, Yumusak N, et al. The preventive effect of dexmedetomidine against postoperative intra-abdominal adhesion in rats. *Inl Surg* 2015; 100:87-95.
- 21-Lobo V, Patil A, Phatak A, Chandra N. Free radicals, antioxidants and functional foods: impact on human health. *Pharmacogon Rev* 2010; 4:118-126.
- 22-Ara C, Kirimlioglu H, Karabulut AB, Cobban S, Hascalik S, Celik O, et al. Protective effect of melatonin against

- oxidative stress on adhesion formation in the rat cecum and uterine horn model. *Life Sci* 2005; 77:1341-50.
- 23-Asadi SY, Parsaei P, Karimi M, Rafiian-Kopaei M. Effect of ethanolic extract of green tea (*Camellia Sinensis*) on intra-abdominal adhesions in rats. *J Zanjan Unive Med Sci* 2013; 21:86-96.
- 24-Jomezadeh V, Mohammadpour AH, Rajabi O, Tavassoli A, Maddah GH. Evaluation of curcumin effects on post-operative peritoneal adhesion in rats. *Iran J Basic Med Sci* 2012; 15: 1162-7.
- 25-Corralesl F, Corralesl M, Schimer C. Preventing intraperitoneal adhesions with vitamin E and sodium hyaluronate/carboxymethylcellulose. A comparative study in rats. *Acta Chirurgia Brasileira* 2008; 23:36-41.
- 26-Alkaadi A, Abdelazim AM. Improved anti-inflammatory effect of Silymarin in rats induced liver carcinogenesis. *Word appl Sci J* 2013; 21:176-80.
- 27-Sabiua S, Sunmonub T, Ajani E, Ajiboye TO. Combined administration of Silymarin and vitamin C stalls acetaminophen-mediated hepatic oxidative insults in wistar rats. *Rv Bras Farmacogn* 2015; 25:29-34.
- 28-Ghaffari a, Noshad H, Ostadi O, Ghojzadeh M, Asadi P. The effects of milk thistle on hepatic fibrosis due to methotrexate in rat. *Hepat Mon* 2011; 11: 464-8.
- 29-Davey Ak, Maher PJ. Surgical adhesions: A timely update, a great challenge for the future. *J Minim Invasive Gynecol* 2007; 14:15-22.
- 30-Williams RS, Rossi AM, Chegini N, Schultz G. Effect of transforming Growth factor beta on postoperative adhesion formation and intact peritoneum. *J Surg Res* 1992; 52:65-70.
- 31- Lucas PA, Warejcka DJ, Young HE, Lee BY. Formation of abdominal adhesions is inhibited by antibody to transforming growth factor-beta1. *J Surg Res* 1996; 65:135-8.
- 32-Jia JD, Bauer M, Cho JJ, Ruehl M, Milani S, Boigk G, et al. Antifibrotic effect of Silymarin in rat secondary biliary fibrosis mediated by downregulation of alpha1 and TIMP-1. *J Hepatol* 2001; 35:392-8.
- 33-Jeong DH, Lee G, Jeong W, Do S, Yang HJ, Yuan DW et al. Alteration of mast cells and TGF- $\beta$ 1 on the silymarin treatment for CCl<sub>4</sub>-induced hepatic fibrosis. *World J Gastroenterol* 2005; 11:1141-8.
- 34-Al-Rasheed NM, Mohammed Fadda L, Al-Rasheed N, Mohamoud Ali H, Yacoub H. Down-regulation of NF $\kappa$ B, Bax, TGF-  $\beta$ , Smad-2mRNA expression in the livers of carbon tetrachloride treated rats using different natural antioxidants. *Braz Biol Technol* 2016; 59:1-10.
- 35- Johnson K E, Wilgus TA. Vascular endothelial growth factor and angiogenesis in the regulation of cutaneous wound repair. *Adv Wound Care* 2015; 3: 647-61.
- 36- Ignjatovica D, Aaslandb K, Pettersen M, Sundc S, Chend Y, Spasojevice M et al. Intra-abdominal administration of bevacizumab diminishes inta-peritoneal adhesions. *Am J Surg* 2010, 200:270-5.
- 37-Jiang C, Agarwal R, Lu J. Anti-angiogenic potential of a cancer chemopreventive flavonoid antioxidant, silymarin: Inhibition of key attributes of vascular endothelial cells and angiogenic cytokine secretion by cancer epithelial cells format. *Biochem Biophys Res Commun* 2000; 276:371-8.
- 38-Guangbing W, Xin C, Guanghui W, Pengbo J, QinHong X, Gaofeng P et al. Inhibition of cyclooxygenase-2 prevents intra-abdominal adhesions by decreasing activity of peritoneal fibroblasts. *Drug Des Devel Ther* 2015; 9:3083-98.
- 39-Wu G, Lue J, Rana JS, Laham R, Selke FW, Li J. Involvement of COX-2 VEGF-induced angiogenesis via P38 and JNK pathways in vascular endothelial cells. *Cardiovasc Res* 2006; 69:512-9.
- 40-Agrwal R, Agarwal C, Ichikawa H, Singh RP, Agarwal BB. Anticancer potential of silymarin: from bench to bedside. *Anticancer Res* 2006; 26:4457-98.