

## Acute Aortic Dissection in Third Trimester Pregnancy- a Case Report

Akram shariati<sup>1</sup>, Dorsa Kavandi<sup>2</sup>, Reza Hajizadeh<sup>3\*</sup>

Received 01 May 2022, Accepted for publication 23 Nov 2022

### Abstract

Acute aortic dissection is a rare but fatal event in pregnancy with a reported incidence of 14% of all cardiac-related maternal mortality. Saving a mother and her baby together in an emergent situation which needs proper decision-making and good teamwork. On the other hand, using standard diagnostic tools such as computed tomography (CT) angiography may not be a good decision as it postpones necessary intervention and causes encounter of the mother and her fetus to a more harmful situation. Here we present a 25-year-old pregnant woman with acute aortic dissection who was diagnosed by echocardiography data. On-time surgical intervention saved a mother and her baby's life. One-year follow-up showed no complication.

**Keywords:** Aortic Dissection, Aortic Rupture, Echocardiography, Pregnancy

**Address:** Department of Cardiology, Urmia University of Medical Sciences, Urmia, Iran

**Tel:** +984433441150

**Email:** hajizadh.reza@gmail.com

### Introduction

Acute aortic dissection (AAD) is a rare but fatal event in pregnancy with a reported incidence of 14% of all cardiac-related maternal mortality (1). It is typically reported during the third trimester or soon after delivery in the postpartum period (2).

Aortic dissection occurs when a longitudinal intimal tear in the aortic wall forms a false lumen in the media layer of the aorta. It is most commonly associated with hypertension, inherited connective tissue disorders, Turner syndrome, and bicuspid aortic valve; whoever it can occur without any risk factor during pregnancy (3).

Physiologic changes especially in the third trimester predispose pregnant women to develop cardiovascular complications like AAD (4).

In this report, we describe a 25-year-old Iranian pregnant woman who presented with palpitation,

dyspnea, and chest pain. The diagnosis of AAD was confirmed after evaluation, and cardiac surgery was performed following cesarean delivery. Mother and baby survived. The patient improved clinically and was discharged home after 5 days.

### Case Report

A 25-year-old previously healthy woman, G2P1, came to the emergency department (ED) at 32 weeks of gestation with dyspnea, palpitation, and chest pain for 3 days. She had no past medical, surgical, or drug history. In physical examination, the patient was conscious and oriented but she appeared ill. The patient did not have Marfanoid, dysmorphic, or syndromic features. She was normotensive with a blood pressure of 115/50 mmHg in both arms and equal right and left radial pulses. Her heart rate was 111 beats/minute, and her respiratory rate

<sup>1</sup> Department of Cardiology, Urmia University of Medical Sciences, Urmia, Iran

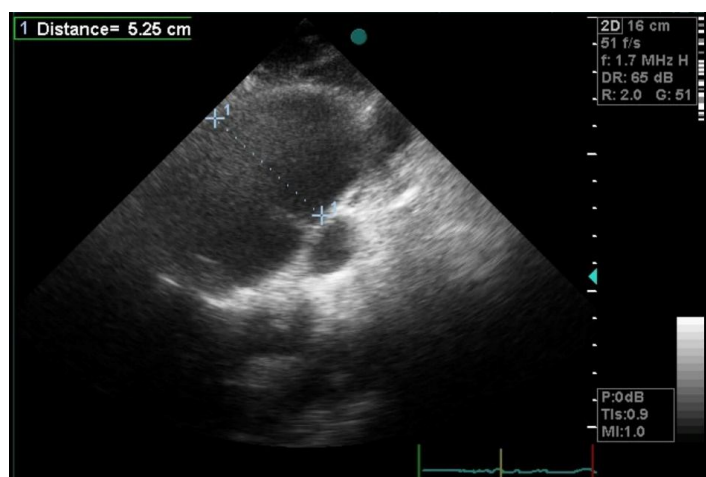
<sup>2</sup> Department of Cardiology, Urmia University of Medical Sciences, Urmia, Iran

<sup>3</sup> Department of Cardiology, Urmia University of Medical Sciences, Urmia, Iran (Corresponding Author)

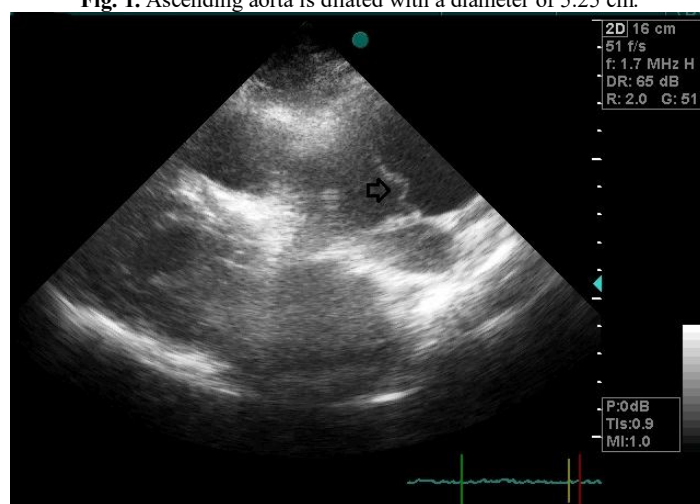
was detected 22 breaths/min with a body temperature of 36.9 on admission. Oxygen saturation was 96%. In cardiac auscultation, a diastolic murmur was heard in the second space right sternal border, and her lungs were clear in auscultation. Not any paradoxical pulse was detected. Jugular veins were not prominent. There was no evidence of cyanosis or edema. Examination of skin and mucosal membranes, eyes, thyroid gland, joints, and

nervous system were unremarkable. The electrocardiogram was normal. Troponin was negative.

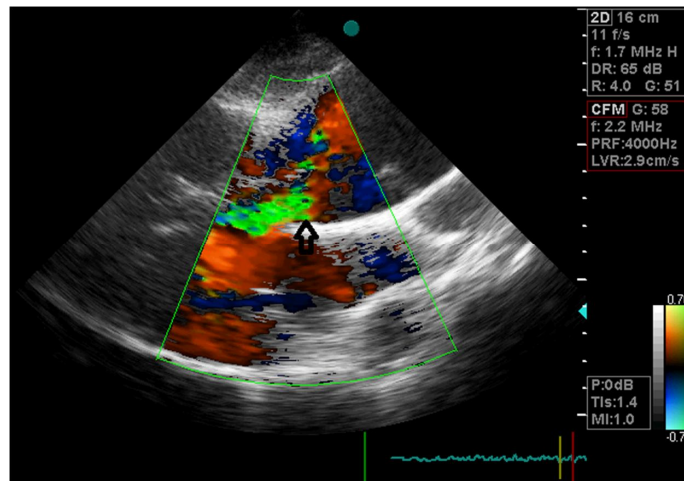
Trans-thoracic echocardiography (TTE) showed a dilated aortic root (4.4 cm) and the ascending aorta (5.25 cm) (Figure 1) with a flap in it (Figure 2) extending to the aortic valve, resulting in moderate to severe aortic valve insufficiency (Figure 3).



**Fig. 1.** Ascending aorta is dilated with a diameter of 5.25 cm.



**Fig. 2.** arrow shows flap in ascending aorta.



**Fig. 3.** moderate to severe aortic valve insufficiency. (arrow)

Further findings included mild pericardial effusion around the right ventricle (RV), mild RV enlargement, mild trabeculation of the left ventricular (LV) apex, and mild mitral and tricuspid valves regurgitation. Left ventricular size and function were normal, and there was no evidence of LV hypertrophy. The diagnosis of AAD was confirmed by echocardiography and because of her critical condition, computed tomography angiography was not done for the patient.

The obstetric and cardiology team decided to perform a single-session delivery and aortic repair/replacement. Thus, the patient was transferred to the operating room and an emergent cesarean section was performed. A live female infant was delivered (Apgar score was normal) and transferred to the Neonatal Intensive Care Unit (NICU).

After cesarean delivery, Intraoperative transesophageal echocardiography (IOTEE) was done and the diagnosis of type A aortic dissection was confirmed. Furthermore, a small secundum type atrial septal defect (ASD) (6 mm) with a left-to-right shunt was seen as an incidental finding.

Cardiopulmonary bypass was done. Ascending aorta replacement with Dacron graft size 24 was done and ASD was closed. Due to severe aortic valve regurgitation, replacement of the aortic valve, ascending aorta, aortic arch, and reimplantation of coronary arteries were done. After the procedure, she was hemodynamically stable and transferred to the Intensive Care Unit (ICU). After a few days, she was clinically improved and control echocardiography revealed no problem and so she discharged home. Follow-ups showed no complication.

## Discussion

Up to 4% of all pregnancies are complicated by cardiovascular diseases, which by including hypertension, this prevalence (rate) reaches 10% (5). Gestational hypertensive disorders, pulmonary embolism (PE), aortic or coronary artery dissection, acute myocardial infarction (AMI), and peri-partum cardiomyopathy (PPCM) are listed in this category (6). Although aortic dissection is a rare condition, it is the most lethal complication in pregnancy with a reported 14% of cardiovascular-related maternal mortality (7).

Aortic dissection occurs when a longitudinal intimal tear in the aortic wall forms a false lumen in the media layer of the wall. It is mostly associated with systemic hypertension, inherited connective tissue disorders (Marfan syndrome, Ehlers-Danlos), Turner syndrome, Loays-Dietz syndrome, and bicuspid aortic valve (8).

In a review article, Yuan SM showed that three quarters of the pregnant patients had at least one risk factor, commonly Marfan syndrome. However, the rest of the patients (one quarter) did not have any predisposing factors (1). Borhart J et al., demonstrated that the incidence of hypertension in the patients with AAD and pregnancy was lower than it in the non-pregnant patients (6). Both studies concluded that pregnancy itself can be a prominent independent risk factor for aortic dissection. Furthermore, Lansman SL et al. mentioned pregnancy as the most common risk factor for AAD in young women although still reported rarely (0.1% to 0.4% of all aortic dissections) (9).

In this case, a young pregnant woman in the third trimester presented with dyspnea, palpitation, and chest pain. She had no underlying cardiovascular and pulmonary disease or no known risk factor predisposing her to aortic dissection. Her previous pregnancy was normal without complications.

AAD is typically reported during the third trimester (50%) or soon after delivery in the postpartum period (33%) (10). Physiologic changes especially in the third trimester of pregnancy are responsible for cardiovascular complications. Increasing intravascular volume up to 50% by 32 weeks of gestational age leads to increased aortic wall stress (tension) and damage to its structure. Additionally, hormonal effects on vascular structure during pregnancy can lead to AAD. Estrogen causes the synthesis and deposition of collagen and elastin in the aortic wall, consequently, decreasing (lowering) the wall strength and accelerating the development of AAD (1). Type A (proximal) aortic dissection in which ascending aorta is involved is more

common and severe during pregnancy and postpartum. It is reported 77% and 67% by Rajagopalan S et al. and De Martino A et al. respectively (11, 12).

Immer FF et al. in a review article demonstrate that type A AAD is more symptomatic than type B, thereby Type A is more likely to be diagnosed clinically. Clinical manifestations of AAD include acute chest discomfort radiating to the back, syncope, nausea, vomiting, sweating, and bronchospasm (13).

During pregnancy, these symptoms are less specific (atypical) and diagnosis is challenging. Therefore, to prevent misdiagnosis and probable life-threatening complications for both mother and fetus, many studies have recommended even in the absence of predisposing risk factors. Aortic dissection must be considered during acute chest pain evaluation during pregnancy, alongside other common causes of acute chest pain including AMI and PE (14).

Electrocardiogram, chest radiography, transthoracic, trans-esophageal echocardiography, and computerized tomography angiography (CTA) or magnetic resonance imaging (MRI) are non-invasive equipment that can help to make a correct diagnosis.

An electrocardiogram may be normal or show signs of left ventricular hypertrophy or acute myocardial infarction if the coronary arteries are involved. Chest radiography in 12% of the cases shows no abnormalities (15). CTA is a useful imaging tool with high sensitivity and specificity for the diagnosis of aortic dissection, but its use is restricted in pregnancy. However, trans-esophageal is the ideal choice for pregnant women as it's similar to CTA in sensitivity and specificity (4).

Electrocardiogram was normal in our patient. According to the patient's emergent condition, chest radiography was not performed. A diastolic murmur in her right upper sternal border in cardiac auscultation revealed the need for TTE. TTE is an available non-expensive method available in most emergency rooms, so it was the best choice to evaluate our patient.

The treatment strategy is dependent on gestational age and type of AAD but, emergent conditions need immediate surgical intervention as soon as possible. Surgery is preferred for type A, and conservative treatment is usually recommended for type B AAD (16).

Proper treatment is achieved by considering the following three main factors: 1. Risk of fetal loss, if pregnancy is continued; 2. Risk of neonatal immaturity, if cesarean delivery is performed; and 3. The risk of maternal death (17). In recent studies, researchers indicate if the fetal chance to survive independently is high (after 28 weeks or 32 gestational age in Zhu JM et al. and Lansman SL et al. studies, respectively), the appropriate choice is primary cesarean section followed by aortic repair. In a single-session delivery and aortic repair, it is better to perform a cesarean section before aortic repair as anticoagulation, and cardiopulmonary bypass may harm the fetus (4, 9).

In our patient, this strategy was done as well. First, cesarean was performed and then with intraoperative TTE, the aortic replacement was performed.

### Conclusion

Aortic dissection is a rare but potentially fatal event during pregnancy. It should be considered when evaluating acute chest pain in pregnant women even in the absence of predisposing factors including hypertension, connective tissue disorders, or bicuspid aortic valve, alongside other more frequent causes like AMI or PE. In order to achieve better outcomes, timely diagnosis, and subsequent appropriate management is necessary.

### References

1. Yuan SM. Aortic dissection during pregnancy: a difficult clinical scenario. *Clin Cardiol* 2013;36(10):576-84.
2. Kinney-Ham L, Nguyen HB, Steele R, Walters EL. Acute Aortic Dissection in Third Trimester Pregnancy without Risk Factors. *West J Emerg Med* 2011;12(4):571-4.
3. Gawinecka J, Schönraht F, von Eckardstein A. Acute aortic dissection: pathogenesis, risk factors and diagnosis. *Swiss Med Wkly* 2017;147:w14489.
4. Zhu JM, Ma WG, Peterss S, Wang LF, Qiao ZY, Ziganshin BA, et al. Aortic Dissection in Pregnancy: Management Strategy and Outcomes. *Ann Thorac Surg* 2017;103(4):1199-206.
5. Ramlakhan KP, Johnson MR, Roos-Hesselink JW. Pregnancy and cardiovascular disease. *Nat Rev Cardiol* 2020;17(11):718-31.
6. Borhart J, Palmer J. Cardiovascular Emergencies in Pregnancy. *Emerg Med Clin North Am* 2019;37(2):339-50.
7. Silvestri V, Mazzei G, Mele R. Postpartum aortic dissection. A case report and review of literature. *Int J Surg Case Rep* 2019;56:101-6.
8. Yang Z, Yang S, Wang F, Wang C. Acute aortic dissection in pregnant women. *Gen Thorac Cardiovasc Surg* 2016;64(5):283-5.
9. Lansman SL, Goldberg JB, Kai M, Tang GH, Malekan R, Spielvogel D. Aortic surgery in pregnancy. *J Thorac Cardiovasc Surg* 2017;153(2):S44-s8.
10. De Martino A, Morganti R, Falcetta G, Sciotti G, Milano AD, Pucci A, et al. Acute aortic dissection and pregnancy: Review and meta-analysis of incidence, presentation, and pathologic substrates. *J Card Surg* 2019;34(12):1591-7.
11. Rajagopalan S, Nwazota N, Chandrasekhar S. Outcomes in pregnant women with acute aortic dissections: a review of the literature from 2003 to 2013. *Int J Obstet Anesth* 2014;23(4):348-56.
12. De Martino A, Blasi S, Bortolotti U. Understanding pregnancy-related aortic dissection-still a long way to go? *J Card Surg* 2021;36(4):1580.
13. Immer FF, Bansi AG, Immer-Bansi AS, McDougall J, Zehr KJ, Schaff HV, et al. Aortic dissection in pregnancy: analysis of risk factors and outcome. *Ann Thorac Surg* 2003;76(1):309-14.

14. Beirer M, Banke IJ, Münzel D, Wendorff H, Khaladj N, Kirchhoff C, et al. Emergency cesarean section due to acute aortic dissection type A (DeBakey I) without Marfan syndrome: a case report and review of the literature. *J Emerg Med* 2014;46(1):e13-7.
15. Johnston C, Schroeder F, Fletcher SN, Bigham C, Wender R. Type A aortic dissection in pregnancy. *Int J Obstet Anesth* 2012;21(1):75-9.
16. Zhu J-M, Ma W-G, Peterss S, Wang L-F, Qiao Z-Y, Ziganshin BA, et al. Aortic Dissection in Pregnancy: Management Strategy and Outcomes. *Ann Thorac Cardiovasc Surg* 2017;103(4):1199-206.
17. Sun HD, Lee WL, Wang PH. Aortic dissection during pregnancy. *Taiwan J Obstet Gynecol* 2020;59(4):627-8.

**Copyright © 2022 Studies in Medical Sciences**

This is an open-access article distributed under the terms of the [Creative Commons Attribution-noncommercial 4.0 International License](https://creativecommons.org/licenses/by-nc/4.0/) which permits copy and redistribute the material just in noncommercial usages, as long as the original work is properly cited.