

Unusual Open Inferior Glenohumeral Dislocation (Luxatio Erecta Humeri) with Illustration Neurovascular Injuries: A Case Report

Hassan Taleb ¹, Ali Tabrizi ², Ahmadreza Afshar ³

Received 26 July, 2020, Accepted for publication 22 November, 2020

Abstract

Luxatio erecta humeri (LEH) refers to a rare glenohumeral dislocation that may be accompanied by neurovascular injuries. Regarding the low prevalence of this type of dislocation, little knowledge is available in this field. This report presents a 40-year-old man with open dislocation in which the humerus head was exposed in the axillary site. Neurovascular injuries also occurred in the form of brachial artery involvement. Extensive tears in the inferior capsule resulted in the lockage and impossibility of closed reduction; thus open reduction was required. A severe instability existed due to the subscapularis tendon rupture and the anterior and inferior capsule. After reduction, tendon and capsule were repaired by ethibond excel nonabsorbable polyester. The patient's movement started 4 weeks after the surgery which exhibited complete stability. 4-month follow-up indicated that the radial and ulnar nerves paralysis were resolved and the normal function was retained. Regarding high neurovascular injuries in the inferior glenohumeral dislocations, a precise vascular examination is of crucial importance. Therefore, attempts for closed reduction may further increase the neurovascular complications.

Keywords: Luxatio Erecta Humeri; Neurovascular injuries; Closed Reduction

Address: Moderres Ave., Imam Khomeini Educational Hospital, Urmia University of Medical sciences, Urmia, Iran

Tel: +989144124481

Email: hassantaleb_dr@yahoo.com

Introduction

Luxatio erecta humeri (LEH) refers to a rare glenohumeral dislocation accounting for about 0.5% of the acute traumatic glenohumeral dislocations. This type of dislocation is characterized by locking in upright-position-luxatio erecta condition. The main underlying mechanism for such dislocation is the direct force applied to the shoulder at full abduction arm status (1). The second mechanism of action involves indirect sudden forceful hyperabduction at the upper extremity abducted condition. Regarding the low prevalence of

this type of dislocation, little knowledge is available in this field; the limited studies in this regard are often presented as a special case (1, 2). In this report, we present a patient with an unusual inferior shoulder dislocation whose humerus head bone was exposed from the axillary site.

Case Report

The patient was a 40-year-old man suffering from right shoulder trauma after a ladder fall accident; his upper extremity was in hyperabduction condition. The

¹ Department of Orthopedics, Imam Khomeini Hospital, Urmia University of Medical Sciences, Urmia, Iran (Corresponding Author)

² Department of Orthopedics, Imam Khomeini Hospital, Urmia University of Medical Sciences, Urmia, Iran

³ Department of Orthopedics, Imam Khomeini Hospital, Urmia University of Medical Sciences, Urmia, Iran

head of the humerus bone could be observed in the axillary site (Fig. 1). During the examination, the distal pulses such as radial and ulnar arteries were not detectable. The patient could not move his shoulder and the organs were fixed at the hyperabduction state (Fig. 2). Wrist and elbow extension was disrupted reflecting radial nerve injury. The examination also indicated the disturbed ulnar nerve. Median nerve sensing and motor operations were normal. The patient was immediately transferred to the operation room. Proper antibiotic treatment was conducted by intravenous penicillin injection. Under general anesthesia and after irrigation and debridement, the axilla was explored to release the arteries trapped in the humerus neck site (Fig. 3). After releasing the arteries, closed reduction was conducted under traction-counter traction which was unsuccessful. Open reduction was thus employed through deltopectoral approach. A severe instability existed due to the subscapularis tendon rupture and the anterior and

inferior capsule. After reduction, tendon and capsule were repaired by ethibond excel nonabsorbable polyester. CT angiography was also conducted to make sure of the intact blood circulation and lack of intimal tear (Fig. 5). The patient was hospitalized for 3 days and treated with antibiotics. After vascular examination, he was discharged from the hospital. In the 4-week follow-up, the movement was carried out in adduction and internal rotation and post-operative antibiotic therapy continued for three days. Customized dynamic splinting was used for the wrist due to radial nerve palsy. The patient's movement started 4 weeks after the surgery which exhibited complete stability. 4-month follow-up indicated that the radial and ulnar nerves paralysis resolved and the normal function was retained. In the follow-up period based on MRI findings, there was a massive rotator cuff tear in the supraspinatus and infraspinatus tendons and they needed a secondary reconstruction.

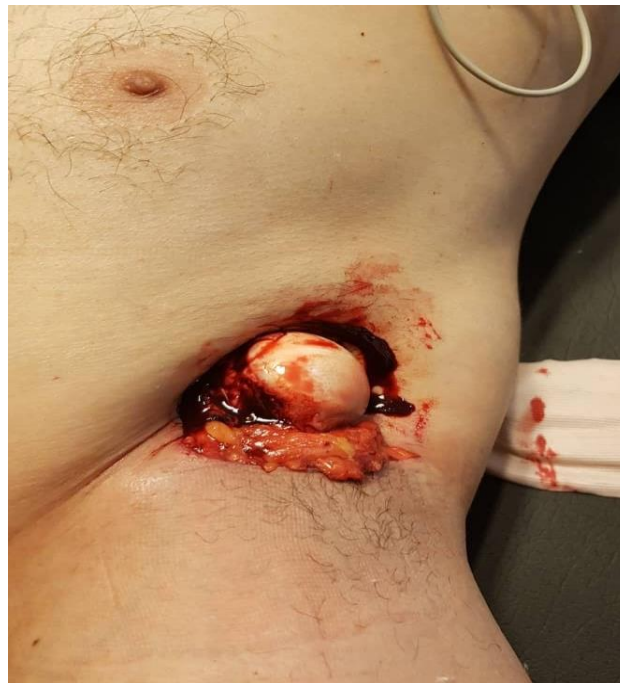

Fig. 1. Clinical photography of patients with open luxatio erecta humeri dislocation and exposure of the humeral head in the axillary site

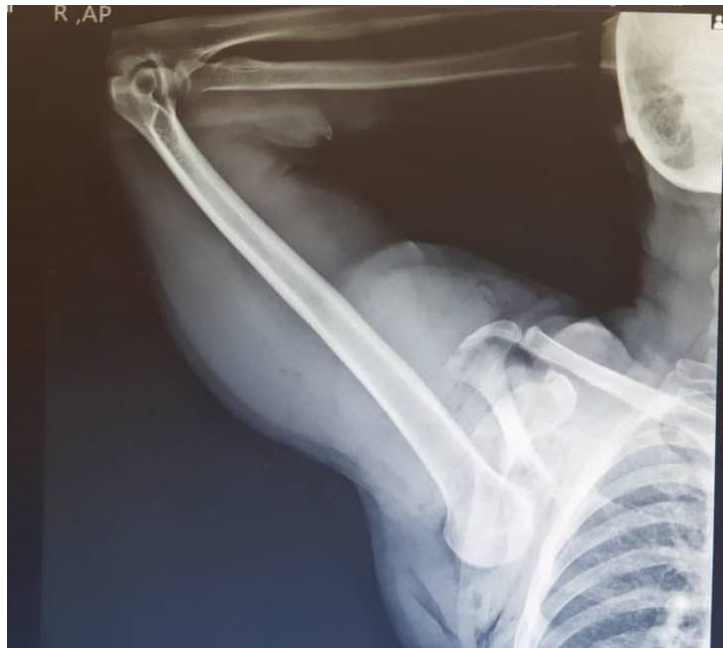

Fig. 2. Pre-reduction radiography indicated inferior glenohumeral dislocation

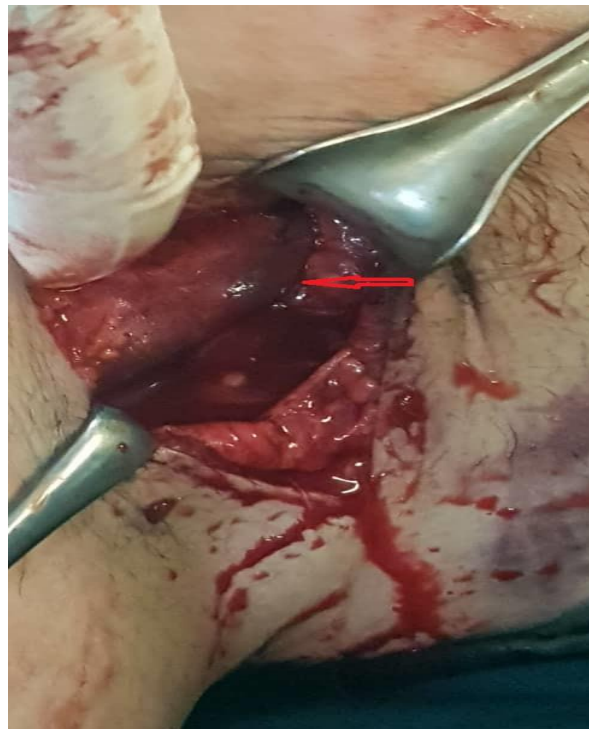

Fig. 3. Clinical photography after open reduction and releasing the brachial artery (The arrow represents the artery)

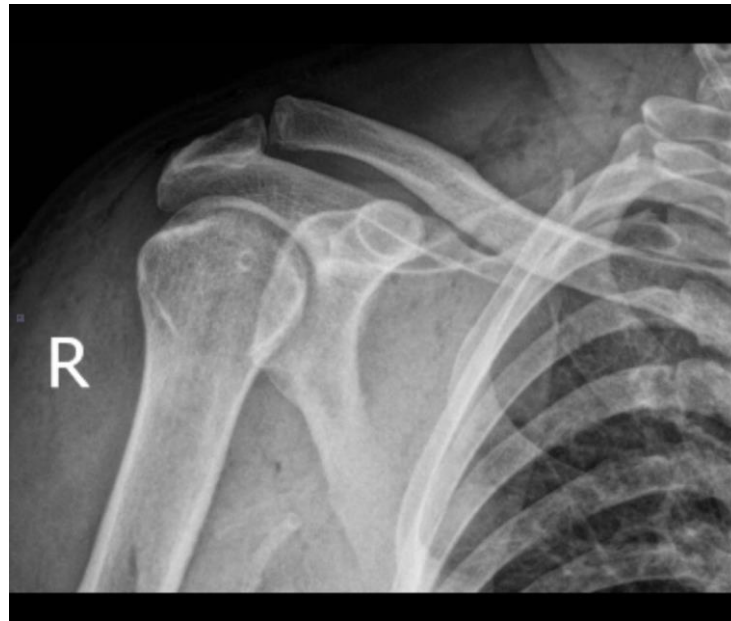

Fig. 4. Post-reduction radiograph showing a concentric reduction of the shoulder joint

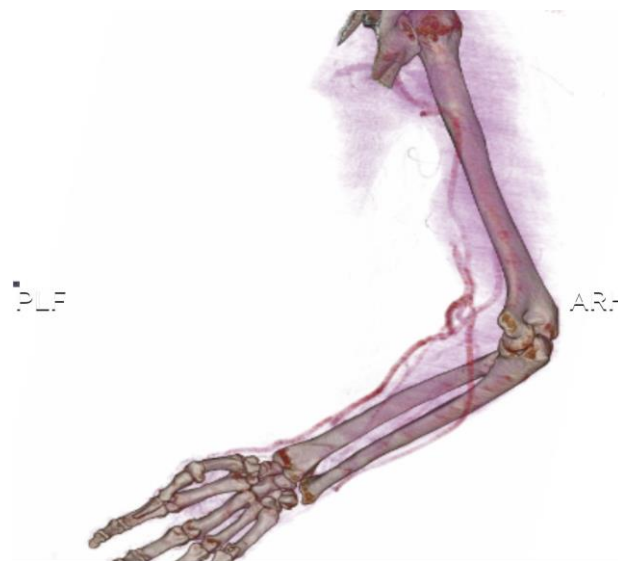


Fig. 5. CT angiography after reduction showing normal circulation

Discussion

Inferior glenohumeral dislocation (known as Luxatio erecta humeri (LEH)) was first presented by Middeldorff and Scharm in 1859 (3). In comparison with the other types of shoulder dislocation, this type is accompanied by more bone and soft tissue complications in a way that acromion, avulsion fracture of the greater tuberosity, clavicle fracture, glenoid, scapular, and acromioclavicular dislocation are more

probable (1,2). According to Mallon et al., simultaneous rotator cuff injuries occur in 12% of these patients (4). In the cases where the humerus head resulted in complete rupture of the inferior capsule, closed reduction may be impossible; hence open reduction is recommended. Moreover, neurovascular injuries are more common in the inferior glenohumeral dislocation (in comparison with the other types of dislocation) (5). According to different reports, about 59% of the

reported neurological injuries were resolved after the reduction (4). Brachial plexus and axillary nerve injuries are also among the common injuries in this type of dislocation. Simultaneous vascular injuries are very rare and the open dislocation in the form of exposed humerus head in the axillary site has not been reported (5). In our case, the open dislocation involved the brachial arteries beneath the humerus neck and caused an extensive rupture in the inferior capsule which resulted in the locking and impossibility of closed reduction. Thus, open reduction was required.

Conclusions

Regarding high neurovascular injuries in the inferior shoulder dislocations, a precise vascular examination is of crucial significance. Attempts for closed dislocation may increase the complications.

Acknowledgement

The authors would like to acknowledge the clinical research development unit of Imam Khomeini hospital, Urmia University of Medical Sciences.

Statement of Ethics

The case report was confirmed by Ethics Committee of Urmia University of Medical Sciences.

Disclosure Statement

There are no conflicts of interest to declare.

Funding Sources

No specific funding was received for this study.

References

1. Saseendar S, Agarwal DK, Patro DK, Menon J. Unusual inferior dislocation of shoulder: reduction by two-step maneuver: a case report. *J Orthop Surg Res* 2009;4(1):40.
2. Gökkuş K, Sagtas E, Saylik M, Aydın AT, Atmaca H. Luxatio erecta humeri: Report of a swimming injury with analysis of the mechanism of the injury and associated injuries in literature. *J Emerg Trauma Shock* 2015;8(1):43-8.
3. Middeldorpf M, Scharm B. De nova humeri luxationis specie. *Clin Eur* 1859;2:12-6.
4. Mallon WJ, Bassett FH III, Goldner RD. Luxatio erecta: the inferior glenohumeral dislocation. *J Orthop Trauma* 1990;4:19-24.
- Owen D, Nambiar M, Moore P, Thomas M. Luxatio erecta humeri with neurovascular compromise: inferior glenohumeral dislocation illustrating associated injuries. *BMJ Case Rep* 2016; 2016: bcr2016217120.